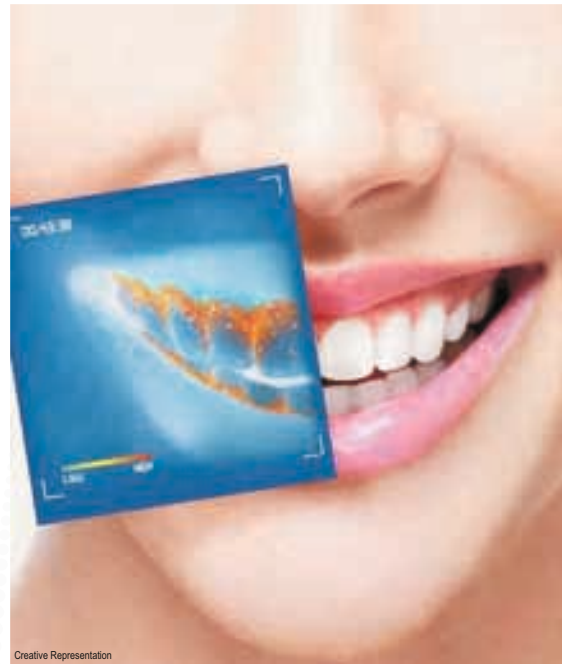

**Immediately after brushing,
germs come back and start multiplying¹**



**Hence there is a need for
12-hour germ protection with Colgate Total^{® 2,3}**

Colgate Total is clinically proven to;

- Reduce plaque by up to 98%^{4,5}
- Reduce gum bleeding by up to 88%^{4,5}
- Reduce tartar by up to 55%^{4,6}
- Provide pleasant breath for up to 12 hours⁷



Fights 12 teeth and gum problems⁸

References:

1. Loesche WJ. Dental Caries: A Treatable Infection. Springfield, Illinois: Charles Thomas; 1982:64-66. 2. Amornchat C, Kraivaphan P, Triratana T, Mahidol Dent J. 2004;24:103-111. 3. Kruger LJ, Murphy CM, Sullivan RJ. Demonstration of the sustained effect of Colgate Total by confocal microscopy. Poster presented at: American Association for Dental Research, March 7-10, 2001; Chicago, IL. Abstract 1031. 4. Panagkos FS, Volpe AR, Petrone ME. J Clin. Dent. 2005; 16 (Suppl): S1-S19. 5. Garcia-Godoy F, Garcia-Godoy F, DeVizio W, Ferlauto R, Miller J. Am J Dent 3 (Spec Issue): S15-26, 1990. 6. Banoczy J, Sari K, Schiff T, Petrone M, Davies R, Volpe A. Anticalculus Efficacy of Three Dentifrices. Am J Dent 8: 205-208, 1995. 7. Hu D. Oral Diseases (2005) 11 (Suppl. 1), 51-53. 8. Data on File, Colgate Palmolive Company.



* Vs a regular fluoride toothpaste

Colgate

YOUR PARTNER IN ORAL HEALTH

www.colgateprofessional.co.in

September-December 2012 Vol. 2 No. 3 **Journal of Contemporary Dentistry** ISSN 2278-2680

September-December 2012

Volume 2

Number 3

ISSN 2278-2680
eISSN 2279-0217



Journal of Contemporary Dentistry

Also available online at
www.jaypeejournals.com
www.jcontempdent.com

Bibliographic Listing:
IndexCopernicus



The Official Publication of
Mahatma Gandhi Mission Dental College & Hospital
Kamothe, Navi Mumbai, Maharashtra, India

 **JAYPEE**

Also Available...



International Journal of **Experimental Dental Science**

(An official journal of Experimental Medical and Dental Science Research Association)

Presentation: Full Color
Cover Type: Soft Cover
ISSN: 2278-1692
eISSN: 2278-1706
Size: 8.25" × 11.75"
Issues: 2

Editor-in-Chief
Rajiv Saini (India)
Executive Editor
Piero Pollicchio (USA)

For more details log on www.ijeds.com



Journal of **Orofacial Research**

Presentation: Full Color
Cover Type: Soft Cover
Size: 8.25" × 11.75"
ISSN: 2277-7482
eISSN: 2249-9091
Issues: 4

Editor-in-Chief
NS Yadav (India)

For more details log on www.jofr.com



Advertising & Marketing

Dedicated to Mark Your Presence in Medical Fraternity

We Extend Our Effectual Support in Form of:

**Advertisement | Bulk Subscription | Reprints | e-Prints
Online Advertisement | Customization | CME | Endorsements**

- Our tactical and conversant publishing team owns a targeted approach to aid you in designing customized market solutions to make you reach key markets and also enjoy business proliferation with our competitive pricing.
- Being world's leading, extensive medical publishers, our state-of-art products and services developed under the close association of local and international medical experts meet your marketing and educational program requirements productively.
- Our growing international associations give you a platform to experience campaign on global front.
- Our PER division includes a team of renowned doctors and specialists to undertake content management for your products and services.

Explore more at:
www.jaypeejournal.com



Domestic & Overseas Branches

Ahmedabad • Belgaum • Bengaluru • Chandigarh • Chennai • Coimbatore • Delhi • Guwahati • Hyderabad
Kochi • Kolkata • Lucknow • Mangalore • Mumbai • Nagpur • Patna • Pune • Vijayawada
Panama • Philadelphia • London • Nepal • Bangladesh

Corporate Office
4838/24 Ansari Road, Daryaganj, New Delhi 110 002, India
Phone: 91-11-43574357
e-mail: advertisements@jaypeejournal.com

September-December 2012 Volume 2 Number 3 ISSN 2278-2680

Executive Advisory Board

Sabita M Ram
Jyotsna Galinde
Girish Karandikar

Editor-in-Chief

Richard Pereira

*Journal of
Contemporary
Dentistry*



The Official Publication of
Mahatma Gandhi Mission Dental College & Hospital
Kamothe, Navi Mumbai, Maharashtra, India



www.jaypeebrothers.com
www.jaypeejournals.com

Journal of Contemporary Dentistry

1. Aims and Scope

The Scientific Journal of the Mahatma Gandhi Mission Dental College was launched in June 2011.

This journal is dedicated to increasing scientific exchange across college departments and to encourage postgraduates, staff and students to be involved in scientific literary work.

This journal also endeavors to promote a multidisciplinary outlook in dentistry. This journal publishes evidence-based original scientific articles presenting relevant and useful information to all dentists. Additionally, it publishes case reports of innovative techniques, new instructional methodologies and instructive clinical reports with an interdisciplinary flair.

The journal is particularly focused on promoting and positioning the scientific edge of this institution to the outside world.

2. Ethical Considerations

Manuscripts submitted for publication must comply with the following ethical considerations:

Informed Consent

Informed consent of the patients must be taken before they are considered for participation in the study. Patient identifying information, such as names, initials, hospital numbers, or photographs should not be included in the written descriptions. Patient consent should be obtained in written and archived with the authors.

Protection of Human Subjects and Animals in Research

When conducting experiments on human subjects, appropriate approval must have been obtained by the relevant ethics committees. All the procedures must be performed in accordance with the ethical standards of the responsible ethics committee both (institutional and national) on human experimentation and the Helsinki Declaration of 1964 (as revised in 2008). When reporting experiments on animals, authors must follow the institutional and national guidelines for the care and use of laboratory animals.

3. Copyright

Following guidelines must be followed before submission of the manuscript:

The articles must represent original research material, should not have been published before, and should not be under consideration of publication else where. This, however, does not include previous publication in form of an abstract or as part of published literature (review or thesis). It is the duty of the author to obtain the necessary permissions for extensive quotations, tables, illustrations or any other copyrighted material they are using in the paper before a paper can be considered for publication. Copyright of the article gets transferred to Jaypee Brothers, once the article has been accepted for publication. The author would be asked to sign the "Copyright Transfer Form" before his/her article is considered for publication. Once the Copyright Transfer statement has been signed by the corresponding author, no change in authorship or in the order of the authors listed on the article would be accepted by Jaypee Brothers. Also by signing the above mentioned form, the author reassigns the rights of copublishing, or translation if considered necessary in future to the publisher. In the advent of occurrence of any dispute, the matter would be resolved within the jurisdiction of New Delhi court.

While all care has been taken to provide accurate and correct information in accordance with the date of publication, neither the authors, editors nor the publisher takes any legal responsibility for any unintentional omission or error. The publisher makes no expressed or implied warranty with respect to the information contained herein. The published material cannot be photocopied for the following purposes: General distribution, promotion, new works or resale. If this is required, specific written permission requires to be obtained from the publisher. Exclusive rights to reproduce and distribute the articles in this journal have been protected by copyright. This also covers the rights to reproduce or distribute the article as well as the translation rights. No material published in this journal can be reproduced in digital format or stored in form of electronic databases, video disks, etc.

Both the conflict of interests and financial disclosure needs to be handled well while conducting the research study. Disclosure of such relationships is also important in connection with all articles submitted for publication. Both of these

have also been included in the copyright transfer form. Authors should give due acknowledgement to the individuals who provide writing or other assistance while conducting the research study and also disclose the funding source for the research study.

4. Subscription Information

ISSN 2278-2680
eISSN 2279-0217

• **Subscription rates**

For information on subscription rates and the other journal related enquiries please contact:

journals@jaypeebrothers.com

• **Orders**

Journals Department
Jaypee Brothers Medical Publishers (P) Ltd.
4838/24, Ansari Road, Daryaganj
New Delhi 110 002, India
Phone: +91-11-4357 4357
Fax: +91-11-4357 4314
e-mail: subscriptions@jaypeejournal.com

5. Electronic Media

An electronic edition of this journal is available at www.jaypeejournal.com
Manuscripts can be submitted online at www.jcontempdent.com

6. Advertisement

For advertisement queries please contact:

Journals Department
Jaypee Brothers Medical Publishers
e-mail: advertisements@jaypeejournal.com

For any queries regarding online submission, please e-mail us at: help-desk@jaypeejournal.com

For editorial queries, please contact:
chetna.malhotra@jaypeebrothers.com

The Journal is printed on acid free paper.

Copyright
© Jaypee Brothers Medical Publishers (P) Ltd.
www.jaypeebrothers.com
www.jaypeejournal.com

Patrons

Kamal K Kadam

Sudhir N Kadam

Nitin N Kadam

Executive Advisory Board

Sabita M Ram

Jyotsna Galinde

Girish Karandikar

Editor-in-Chief

Richard Pereira

Assistant Editors

Sunil Sidana

Rajesh Patil

Sachin Kanagotagi

Publishing Center

Publisher

Jitendar P Vij

Senior Manager

Chetna Vohra

Managing Editor

Ekta Aggarwal

Editorial Associate

Pankaj K Singh

Creative Designer

Radhe Shyam Singh

Editorial Office

Sabita M Ram, Dean, Professor and Head
MGM Dental College and Hospital
Sector 18, Kamothe, Navi Mumbai-410209
Maharashtra, India
e-mail: jcdent@mgmindia.co.in

Production Office

Jaypee Brothers Medical Publishers (P) Ltd.
4838/24, Ansari Road, Daryaganj
New Delhi-110 002, India
Phone: +91-11-43574357
Fax: +91-11-43574314
e-mail: journals@jaypeebrothers.com

Advertisements

Rakesh Sheoran
Phone: +91-9971020680
e-mail: advertisements@jaypeejournal.com
rakesh.sheoran@jaypeebrothers.com

Subscriptions/Reprints

Abhinav Kumar
Phone: +91-9810279794
e-mail: subscriptions@jaypeejournal.com
abhinav.kumar@jaypeebrothers.com

Website Manager

Rohit Gorawara
Phone: +91-9871855331
e-mail: contact@jaypeejournal.com
rohit.gorawara@jaypeebrothers.com

ADVISORY BOARD

Murali Mohan	RP Nayak
PN Awasthi	VP Jayade
JN Khanna	LS Poonja
Dinesh Daftary	OP Kharbanda
Mahesh Verma	AK Barua
PC Gupta	Rahul Hegde
Sureshchandra Shetty	Mansing Pawar

EDITORIAL REVIEW BOARD

Prosthodontics

Vimal Arora
Suhasini Nagda
Padmanabhan TV
Jyoti Undirwade
Usha Radke
Hetal Turakhia

Maxillofacial Surgery

RR Pradhan
Vinod Kapoor
Suhas Vaze
Rajiv Borle
Rajesh Dhirwani
SC Bohir

Periodontics

Harshad Vijaykar
Mala Dixit
Abhay Kolte
Rajiv Chitguppi
Sudhindra Kulkarni

Pedodontics

Shobha Deshpande
Uma Dixit
Amita Tikku
Thejokrishna P

Oral Pathology

Vinay Hazare
Suresh Barpande
Jagdish Tupkari
Sangeeta Patankar
Sachin Sarode

Conservative Dentistry

Naseem Shah
Manjunath NK
Sharad Kokate
Shishir Singh
Vibha Hegde

Orthodontics

Shalan Karbelkar
Shweta Bhat
Vaishali Vadgaonkar
Jayesh Rahalkar
Nikhilesh Vaid

Oral Medicine

Hemant Umarji
Ajay Bhoosreddy
Freny Karjodkar
Anil Ghom
Deepa Das

Public Health Dentistry

Navin Ingle
Suhas Kulkarni
Charu Mohan
Sabyasachi Saha
Ajay Bhambal
L Nagesh

EDITORIAL COMMITTEE

Tulika Khanna	Zohara Charania
Sumanthini MV	Shwetha Kumar
Rohit Gadda	Shrirang Sevekar

Editorial

From the editorial desk, we wish you dear readers a Very Happy New Year 2013! May the year ahead be a year of academic fulfillment and learning for each one of us...

They say 'what gets measured gets done'; unless we set for ourselves some targets and goals and calibrate our progress toward achieving them, it only remains a pipe dream. During this festive season, we often hear of the clichéd 'new year resolutions', made only to be broken in the 'new year' simply because we are not serious in achieving what we set out to achieve. This new year let us resolve to set ourselves goals of broadening our scientific landscape, thinking and approach. Let us set ourselves that one new year resolution that will enhance our learning and work toward achieving that goal. Maybe attending scientific seminars, symposia, exhibitions and lectures would go a long way in sharpening our scientific saw toward a more evidence-based dental approach or maybe even get down to writing a scientific article.

JCD hopes to contribute to offering you that scientific avenue for contribution toward your scientific goal. We, at the editorial desk, have also set ourselves 'goals' I mentioned in the beginning and are working tirelessly toward achieving them. With the journal becoming online, the articles received are moving beyond the boundaries of this institution and adding a more cosmopolitan feel to the journal. Our effort toward getting it PubMed indexed is very much on and we hope that, with the concerted efforts of driving quality content, we will see it eventually happening in the future.

So, we once again urge you to set for yourself that one goal of putting pen to paper and contributing your scientific literary bit for the next issue. Do have a great year ahead...

Richard Pereira

Professor, Department of Periodontics
MGM Dental College, Navi Mumbai
Maharashtra, India

Journal of Contemporary Dentistry

September-December 2012 Volume 2 Number 3

Contents

RESEARCH ARTICLES

- **Zygomatic Air Cell Defect: Prevalence and Characteristics in Dental Outpatient Population** 69-72
Rohit Gadda, Neha Anil Patil, Rohini Salvi
- **An *in vivo* Study Comparing the Characteristics of Esthetic, Self-ligating and Metallic Brackets** 73-77
*Shashank Sharad Gaikwad, Ashwin Deshpande, Sachin S Doshi
Amol Mhatre, Manish Sonawane*

ORIGINAL ARTICLE

- **Caries Status of Children and Oral Health Behavior, Knowledge and Attitude of Their Mothers and Schoolteachers in Mathura City** 78-83
Ramen Haloi, Navin Anand Ingle, Navpreet Kaur

REVIEW ARTICLES

- **Cone Beam Computed Tomography: Adding the Third Dimension** 84-88
Neha Anil Patil, Rohit Gadda, Rohini Salvi
- **Diagnosis and Treatment of Halitosis: An Overview** 89-95
*Vineet Vaman Kini, Richard Pereira, Ashvini Padhye, Sachin Kanagotagi
Tushar Pathak, Himani Gupta*
- **Etiological Factors of Recurrent Aphthous Stomatitis: A Common Perplexity** 96-100
Niharika Swain, Jigna Pathak, Leela S Poonja, Yogita Penkar

CASE REPORTS

- **Immediate Overdenture** 101-105
Tulika S Khanna, Sandeep Vivek Gurav, Sabita M Ram, DB Nandeeshwar
- **Osteochondroma of the Mandibular Condyle** 106-108
Sushrut Vaidya, Sunil Sidana, Jyotsna Galinde, Srivalli Natrajan
- **Piezography: An Innovative Technique in Complete Denture Fabrication** 109-113
Jayanta Bhattacharyya, Preeti Goel, Soumitra Ghosh, Samiran Das
- **Retreatment of Silver Point Obturation: A Case Report and an Overview** 114-118
Shikha Gulati, MV Sumanthini, Vanitha Shenoy
- **Oral Mucocele: Review and Case Report** 119-124
Mihir Jha, Vivek Jogani

SUBSCRIPTION INFORMATION

Annual Subscription

Individual:	₹ 3500.00	(National)
	\$ 200.00	(International)
Institutional:	₹ 5000.00	(National)
	\$ 280.00	(International)

Subscription can be sent to

M/s Jaypee Brothers Medical Publishers (P) Ltd

Journals Department

Jaypee Brothers Medical Publishers (P) Ltd

4838/24 Ansari Road, Daryaganj

New Delhi 110 002, India

Phone: +91-11-43574357

Fax: +91-11-43574314

e-mail: journals@jaypeebrothers.com

This journal is published thrice in a year, i.e. January, May and September. Dollar rates apply to subscribers in all the countries except India where INR price is applicable. All subscriptions are payable in advance and all the rates include postage. Journals are sent by air to all the countries except Indian subcontinent. Subscriptions are on an annual basis, i.e. from January to December. Payment will be made by dollar cheque, credit card or directly through our bank account at the following address:

1. Our Banker's Name: Canara Bank, Netaji Subhash Marg
Darya Ganj, New Delhi 110 002
2. Telephone No: 011-23273015, 011-23273849
3. Fax No: 011-23255606
4. Telex No: 3166291
5. Our Current A/c No: **3828**
6. Amount to be Transferred
in the Name of: JAYPEE BROTHERS MEDICAL
PUBLISHERS (P) LTD, NEW DELHI
7. Swift Code No: CNRB IN BB DFM

For further queries, please do not hesitate to contact at subscriptions@jaypeejournals.com

ADVERTISEMENT RATES

(For the Print Issues)

Page

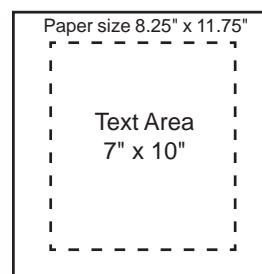
Single issue

Back cover—color	₹ 50,000	\$ 1000.00
Inside front cover—color	₹ 40,000	\$ 800.00
Inside back cover—color	₹ 35,000	\$ 700.00
Inside full page—color	₹ 30,000	\$ 600.00

Special position: **Price on request**

Technical Details

Paper size	8.25 x 11.75 inches
Print size	7 x 10 inches
Digital file format	EPS on CD (at 300 dpi resolution)
Printed on art paper using offset printing.	



Schedule

Issues are published in the months of January, May and September.

Advertisement material along with purchase order and payment should reach us at least four weeks prior to the scheduled print date.

Payment Details

- Payment should favour "Jaypee Brothers Medical Publishers (P) Ltd." and should be payable at New Delhi, India.
- Payment to be done at the time of submitting the advertisement material/booking the advertisement. Please send your advertisement request, payment and advertisement material to the address given above. Editorial board reserves the right to accept or decline the advertisement.

For further queries, please contact advertisements@jaypeejournals.com

Zygomatic Air Cell Defect: Prevalence and Characteristics in Dental Outpatient Population

Rohit Gadda, Neha Anil Patil, Rohini Salvi

ABSTRACT

Aim: To determine the prevalence, radiographic appearance and characteristics of patients with zygomatic air cell defect (ZACD).

Materials and methods: Routine panoramic radiographs of 400 patients who were visited the dental outpatient of our institute were examined retrospectively.

Results: Out of 400 study subjects, ZACD was found in 11, giving an overall prevalence of 2.75%. Out of 11 ZACD subjects, six were males and five were females. The mean age of subjects with ZACD was 33.9 (± 15) years and a range of 18 to 65 years. The bilateral involvement of ZACD was seen in only one subject.

Conclusion: The overall prevalence of ZACD is relatively low in present study population. Knowledge of ZACD may be helpful in interpreting panoramic radiographs, in planning surgical treatment of the temporomandibular joint and in understanding the spread of pathological processes into the joint.

Keywords: Panoramic radiography, Zygomatic, Mastoid, Temporal bone.

How to cite this article: Gadda R, Patil NA, Salvi R. Zygomatic Air Cell Defect: Prevalence and Characteristics in Dental Outpatient Population. *J Contemp Dent* 2012;2(3):69-72.

Source of support: Nil

Conflict of interest: None declared

INTRODUCTION

Pneumatization refers to the presence or development of air-filled cavities in a bone. In addition to the major paranasal sinuses, accessory air cells may arise in numerous locations in the skull, including the temporal bone, either singly or in clusters.^{1,2} Tyndall and Matteson³ coined the phrase 'zygomatic air cell defect' (ZACD) specifically to describe accessory air cells which occur in the root of the zygomatic arch and in the articular eminence of the temporal bone.³

The ZACD has defined as an accessory air cells in the zygomatic process and articular eminence of the temporal bone which appears similar to the mastoid air cells and which does not extend further anteriorly than the zygomatico-temporal suture.^{3,4} The ZACD appears as an asymptomatic radiolucent defect in the zygomatic process of the temporal bone without enlargement or cortical destruction of the zygoma in radiographs.³

There have been case reports on ZACD in the dental literatures.^{3,5-7} In 1976, Roser et al⁶ reported a case of pneumatization of the root of the zygomatic arch that was observed incidentally on a panoramic radiograph obtained as part of an examination of the temporomandibular joint (TMJ). Kulikowski et al⁷ reported the discovery of an air cells in the zygomatic arch of a patient who was undergoing surgical removal of the articular eminence for the treatment of chronic severe condylar subluxation. Tyndall and Matteson³ re-emphasized the occurrence of ZACD and presented three cases discovered in panoramic radiographs. Several authors^{8,9} have suggested the importance of air cells as possible complicating factor during surgical procedure.

Panoramic radiograph is a useful technique to display the ZACD of temporal bone, since the posterior aspect of the zygomatic arch is usually displayed.^{8,9} Computed tomography has been used for this purpose¹⁰ but the cost makes its use difficult to justify. A few series have reported the prevalence of ZACD on panoramic radiographs in general populations.^{4,9,10} Tyndall and Matteson⁸ provided the first detailed data on prevalence and patient characteristics of pneumatized articular eminence of the temporal bone in 1985. Of a series of 1,061 panoramic radiographs, pneumatization of the articular eminence was found in 28 cases (2.6%) with no gender predilection. Most recently, Carter et al⁴ described ZACD in 40 patients (1.5%) out of 2,734 dental clinic outpatients.

The purpose of this study is to determine the prevalence, radiographic appearance and characteristics of the patients with ZACD among the dental out patient population.

MATERIALS AND METHODS

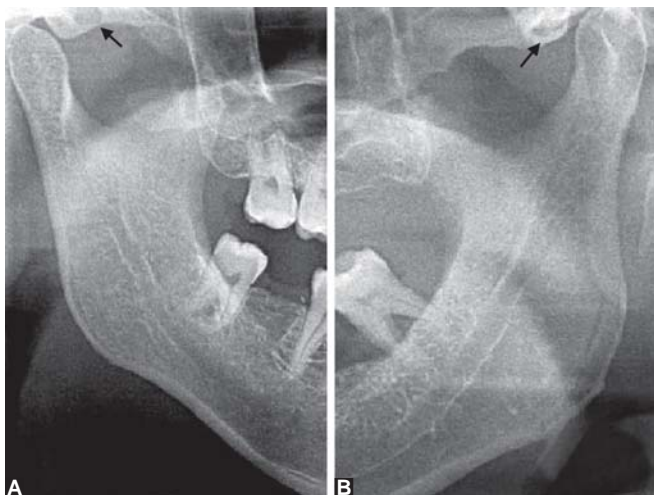
Routine panoramic radiographs of 400 patients who were visited the dental outpatient of our institute were examined retrospectively. Cases in which the zygomatic arch was not adequately displayed for anatomical or technical reasons were excluded from the sample and did not constitute part of the 400-patient sample. Subjects with developmental malformations of the face and jaws, those in whom systemic conditions had affected growth, those with clinical or radiographic evidence of pathologies in the maxillofacial region, and those with a history of trauma to the

maxillofacial region and who had been treated with surgical intervention were excluded from the study.

Panoramic radiograph of subjects were obtained using Kodak 8000 C (Carestream Health India Pvt Ltd). Panoramic radiographs were examined by two oral and maxillofacial radiologists and consensus diagnosis was recorded (Figs 1A and B). Subjects were recorded as having ZACD only if unequivocal pneumatization of the root of zygomatic arch or articular eminence posterior to the zygomaticotemporal suture as a well-defined uni- or multilocular radiolucency could be viewed on the radiograph. The age, gender of the patients who had ZACD and its location, radiographic appearance was also recorded. The radiographic appearance was classified into two types, unilocular and multilocular. Unilocular ZACD was defined as single oval radiolucent defect with well-defined border and multilocular ZACD as numerous small radiolucent defects similar to the mastoid air cells. Also, whether ZACD is unilateral or bilateral was recorded.

RESULTS

The mean age of the 400 patients in the current study was 31.5 (±16.8) years and an overall range of 3 to 78 years.



Figs 1A and B: Cropped panoramic radiographs display typical appearance of ZACD: (A) right side (B) left side

There were 201 males and 199 females in the study population. The mean age of the males was 32.2 (±18.4) years and a range of 3 to 78 years, while that for the females was 30.8 (±15.1) years and a range of 5 to 76 years.

Out of 400 study subjects, ZACD was found in 11, giving an overall prevalence of 2.75%. Out of 11 ZACD subjects, six were males and five were females. The mean age of subjects with ZACD was 33.9 (±15) years and a range of 18 to 65 years (Table 1). The bilateral involvement of ZACD was seen in only one subject. Out of unilateral cases (10), six were on right side (Table 2). All ZACD were unilocular.

DISCUSSION

The cause of ZACD is unknown but may be similar to that of pneumatization of the mastoid process. Pneumatization begins with the formation of small osseous cavities created by normal periosteal activity.¹⁰ Primitive bone marrow in these cavities dedifferentiates into a loose mesenchymal connective tissue. Epithelium invaginates into this connective tissue, producing a mucous membrane which then undergoes atrophy, leaving a thin residual lining membrane attached to the periosteum. Continued sub-epithelial bone resorption further expands the air cells.¹¹

The primary regions of pneumatization of the temporal bone consist of the middle ear, squamomastoid (mastoid), perilabyrinthine, petrous apex and accessory. The accessory regions include the squamous, the zygomatico-occipital and the styloid. The tegmental or periantral air cell may extend into the zygomatic arch, producing the ZACD.¹⁰

A few series have reported the prevalence of ZACD in general populations. Tyndall and Matteson⁸ found 28 cases (2.6 %) of 1,061 panoramic radiographs with a mean age of 32.5 years and an age range of 15 to 74 years. No gender predilection was found and five cases were bilateral. They obtained the sample of cases from a group of mostly adult patients. Kaugars and associates⁹ described pneumatization in the articular eminence in eight (1%) out of 784 panoramic radiographs reviewed. A mean age of eight cases was

Table 1: Age and gender distribution and location of ZACD

S. no.	Gender (male/female)	Age (years)	ZACD (unilateral/bilateral)
1	Male	45	Bilateral
2	Male	44	Unilateral
3	Male	60	Unilateral
4	Male	30	Unilateral
5	Male	26	Unilateral
6	Male	19	Unilateral
7	Female	31	Unilateral
8	Female	29	Unilateral
9	Female	19	Unilateral
10	Female	28	Unilateral
11	Female	18	Unilateral

Table 2: Involvement side in ZACD

	Right	Left
Unilateral (10)	6	4
Bilateral (1)	1	1

45.9 years with age range of 32 to 69 years. Seven patients of them were female and one was male. Four cases were unilateral and four were bilateral. Carter et al⁴ reported 40 cases (1.5%) with ZACD in 2,734 dental clinic outpatients. Patients with ZACD had a mean age of 49.6 years and a range of 17 to 83 years. A total of 32 cases were unilateral and there was no gender predilection.

In the present study, ZACD was found in 11 cases (2.75%) with a mean age of 33.9 years and an age range of 18 to 65 years. There was almost equal gender distribution (six males, five females). Ten subjects of them were unilateral ZACD. In case of unilateral involvement, six of them involved the right side. The present study revealed demonstrable similarities in the prevalence and involvement of ZACD to the previous studies.^{4,8,9} All of the series including this study showed low prevalence.

Two possible reasons for ZACD's being seen less often are: (1) The number of ZACD may be small as there is a wide variability in the extent of accessory air cell of temporal bone. (2) In panoramic radiograph, radiographic visualization of ZACD is more difficult because there are superimposition of adjacent anatomic structures. High-resolution computed tomography (CT) can give a better visualization in the evaluation of bony structure allowing exact delineation of temporal air spaces,¹⁰ but it is not justified because of cost and inconvenience.

In the present study, bilateral involvement of ZACD was seen in only one case. Tyndall and Matteson (17.9%),⁸ Carter and his associates (20%)⁴ demonstrated that ZACD was bilateral in approximately one-fifth of cases.

The differential diagnosis of radiolucencies within the zygomatic arch include ZACD, aneurysmal bone cyst, hemangioma, giant cell tumor, eosinophilic granuloma, fibrous dysplasia and metastatic tumor.¹²⁻¹⁴ Only the ZACD occurs in the zygomatic arch with any frequency and presents as an asymptomatic, nonexpansile, nondestructive radiolucency detected incidentally on radiograph. All of the other entities in the differential diagnosis including osseous hemangioma is a rare lesion in zygoma and would be characterized by enlarging and painful cheek, bony expansion with cortical destruction and frequently mixed density lesions.¹²⁻¹⁴

The clinical significance of ZACD is that they represent sites of minimal resistance and thus facilitate the spread of various pathologic processes into the TMJ such as tumors,

inflammation or fractures and that they may be possible complicating factors during TMJ surgery.¹⁵ Inadvertent violation of an air cell during eminectomy, producing communication with the infratemporal or middle cranial fossa poses the genuine danger of intracranial infection and/or hemorrhage.⁷ This points out the need for thorough pre-operative imaging evaluation.

CONCLUSION

It is of utmost importance that radiologists, diagnosticians and surgeons be aware of this entity so that precise identification can be made, which not only prevents unnecessary investigations and explorations but also forewarns the surgeon and thus helps prevent potential complications.

REFERENCES

1. Tremble GE. Pneumatization of the temporal bone. *Arch Otolaryngol* 1934;19:172-82.
2. Srikanth HS, Patil K, Mahima VG. Zygomatic air cell defect: A panoramic radiographic study of a South Indian population. *India J Radiol Imag* 2010;20:112-14.
3. Tyndall DA, Matteson SR. The zygomatic air cell defect on panoramic radiographs. *Oral Surg Oral Med Oral Pathol* 1987; 64:373-76.
4. Carter LC, Haller AD, Calamel AD, Pfaffenbach AC. Zygomatic air cell defect (ZACD): Prevalence and characteristics in a dental clinic outpatient population. *Dentomaxillofac Radiol* 1999;28: 116-22.
5. Deluke DM. Pneumatization of the articular eminence of the temporal bone. *Oral Surg Oral Med Oral Pathol Oral Radiol Endod* 1995;79:3-4.
6. Roser SM, Rudin DE, Brady FA. Unusual bony lesion of the zygomatic arch. *J Oral Med* 1976;31:72-73.
7. Kulikowski BM, Schow SR, Kraut RA. Surgical management of a pneumatized articular eminence of the temporal bone. *J Oral Maxillofac Surg* 1982;40:311-13.
8. Tyndall DA, Matteson SR. Radiographic appearance and population distribution of the pneumatized articular eminence of the temporal bone. *J Oral Maxillofac Surg* 1985;43: 493-97.
9. Kaugars GE, Mercuri LG, Laskin DM. Pneumatization of the articular eminence of the temporal bone: Prevalence, development, and surgical treatment. *J Am Dent Assoc* 1986;113:55-57.
10. Virapongse C, Sarwar M, Bhimani S, Sasaki C, Shapiro R. Computed tomography of temporal bone pneumatization: 1. Normal pattern and morphology. *AJNR* 1985;6:551-59.
11. Beaumont GD. The effects of exclusion of air from pneumatized bones. *J Laryngol Otol* 1966;80:236-49.
12. Eveson JW, Moos KF, MacDonald DG. Aneurysmal bone cyst of the zygomatic arch. *Br J Oral Surg* 1978;15:259-64.
13. Jeter TS, Hackney FL, Aufdemorte TB. Cavernous hemangioma of the zygoma: Report of cases. *J Oral Maxillofac Surg* 1990;48: 508-12.
14. Savastano G, Russo A, Dell'Aquila A. Osseous hemangioma of the zygoma: A case report. *J Oral Maxillofac Surg* 1997;55: 1352-56.

15. Weinberg S. Eminectomy and meniscorrhaphy for internal derangements of the temporomandibular joint. *Oral Surg Oral Med Oral Pathol* 1984;57:241-49.

ABOUT THE AUTHORS

Rohit Gadda (Corresponding Author)

Senior Lecturer, Department of Oral Medicine and Radiology, MGM Dental College and Hospital, Navi Mumbai, Maharashtra, India
e-mail: rohitgadda@gmail.com

Neha Anil Patil

Senior Lecturer, Department of Oral Medicine and Radiology
MGM Dental College and Hospital, Navi Mumbai, Maharashtra
India

Rohini Salvi

Professor and Head, Department of Oral Medicine and Radiology
MGM Dental College and Hospital, Navi Mumbai, Maharashtra
India

An *in vivo* Study Comparing the Characteristics of Esthetic, Self-ligating and Metallic Brackets

Shashank Sharad Gaikwad, Ashwin Deshpande, Sachin S Doshi, Amol Mhatre, Manish Sonawane

ABSTRACT

The aim of this *in vivo* study was to compare the characteristics of esthetic, self-ligating brackets (SLBs) and metallic brackets, to find bracket bond failures with SLBs and manually ligating brackets (MLBs), bracket breakages with SLBs and MLBs and staining with the SLBs. Seven patients were compared in each group. Standard light curing bonding methods were used in both the groups. Chairside time saving, appliance efficiency and bracket bond failures were compared among the groups whereas staining was observed with the SLBs. Appliance efficiency was evaluated by peer assessment rating (PAR) scores. Results showed significant chairside time being saved in SLBs, whereas the appliance efficiency was not significant. Bond failures were found only in SLBs as well as breakages along with staining. Henceforth, we could conclude that though SLBs had advantage of saving chairside time but also had disadvantage of losing more time with bond failures.

Materials and methods: Two groups of seven patients were created: First group (seven patients) received treatment with OPAL SLBs (Ultradent products, USA) and second group (seven patients) received treatment with MLBs manually ligating metal brackets (Nu-Edge, TP Orthodontics, USA). Case selection was done for both the groups. Bonding procedure was done in both groups in which primer application was done on both tooth surface and bracket base in case of OPAL SLB's while in case of MLBs, primer was applied only on tooth surface. A questionnaire was evaluated for knowing patients comfort.

Results: Comparison of mean values of PAR scores in both the groups for pre-, post-treatment and in the reduction of PAR scores was done.

It showed that SLBs were 6.5 times quicker than the MLBs during the archwire changes, thus saving considerable chairside time. Treatment outcome after 120 days, in both groups was almost the same. The SLBs had many bracket bond failures while MLBs had none. SLBs had other shortcomings, such as bracket breakage, staining, cap opening, etc.

Keywords: Self-ligating brackets, Manually ligating brackets, PAR test.

How to cite this article: Gaikwad SS, Deshpande A, Doshi SS, Mhatre A, Sonawane M. An *in vivo* Study Comparing the Characteristics of Esthetic, Self-ligating and Metallic Brackets. *J Contemp Dent* 2012;2(3):73-77.

Source of support: Nil

Conflict of interest: None declared

INTRODUCTION

Evolution of brackets is a field involving constant innovations with the aim of pleasing both the orthodontists and patients. New brackets are constantly being developed to make the treatment a more pleasing experience for the patient. Introduction of self-ligating brackets (SLBs) in 1935

by Dr Jacob Stolzenberg left many practitioners unfamiliar with the advantages of these revolutionary SLBs. The mechanism of ligation in these revolutionary brackets was in stark contrast to the traditional approach of tying steel ligatures around each bracket. Treatment was considerably more comfortable with shorter office visits and shorter overall treatment time. Perhaps because Dr Stolzenberg was ahead of his time, the concept of SLBs fell more or less into obscurity until the early 1970s.¹ In 1971, Dr Jim Wildman of Eugene, Oregon, developed the Edgelok bracket.² And in the process many a SLBs^{1,3-6} followed suite.

OPAL SLBs (Ultradent, UK) fabricated with glass filled (nickel free) polycarbonate were introduced in year 2004. To our knowledge, no study was carried out to evaluate this type of new SLB. Hence, the need for this study was felt.

Our study was, therefore, aimed at evaluating the chairside time saved, patients' comfort, appliance efficiency, bracket bond failures, breakages and bracket staining in the Opal SLBs and comparing them with the conventional standard metal brackets of MBT system (TP Orthodontics, UK).

AIMS AND OBJECTIVES

Evaluate and compare:

1. Chairside time savings with SLBs and manually ligating brackets (MLBs)
2. Appliance efficiency in leveling and aligning of SLBs and MLBs
3. Patients' comfort with SLBs and MLBs
4. Bracket bond failures with SLBs and MLBs
5. Bracket breakages with SLBs and MLBs
6. Staining with the SLBs.

MATERIALS AND METHODS

All cases were selected from the Department of Orthodontics, PMNM Dental College, Bagalkot, Karnataka. Out of 20 cases, six cases (three in each group) were excluded from the study for discontinuation of treatment by the patients. This reduced the overall number to 14 cases (seven in each group).

Thus, 14 patients were included in the study. Two groups of seven patients were created: First group (seven patients) received treatment with OPAL SLB's (Ultradent products, USA; Fig. 1A) and second group (seven patients) received treatment with MLB's manually ligating metal brackets (Nu-Edge, TP Orthodontics, USA; Fig. 1B).

Case selection criteria were done for both the groups:

- Age of 15 to 25 years
- A minimum score of 10 on peer assessment rating (PAR)
- No history of trauma to the orofacial region
- No history of orthognathic surgery and/or previous orthodontic treatment
- No known congenital craniofacial anomaly
- Treatment plan required no extractions.

Bonding procedure for the conventional MLBs involved (Fig. 2):

- 1st step: Etching
- 2nd step: Primer application on tooth surfaces only
- 3rd step: Adhesive on bracket base.

Bonding procedure for the OPAL SLBs involved (Figs 3A to C):

- 1st step: Etching
- 2nd step: Primer application on both tooth surface and bracket base
- 3rd step: Adhesive on bracket base.

Various parameters were evaluated as below:

1. *Chairside time evaluation:* Only one operator, operated, having no prior experience in the usage of both the bracket systems. In both the groups, the time required to remove and replace the archwire in either the maxillary and mandibular arch from the right second premolar to the left second premolar was noted. The time recorded was solely related to the removal or replacement of the ligature tie and did not involve manipulation of the archwire. The time was recorded using a stopwatch which was recorded by a trained staff. The operator announced the start and completion of upper and lower archwire removal and placement and

the time taken was noted. This time data was divided by the number of brackets present to calculate the average time taken for each bracket.

2. *Appliance efficiency (in leveling and aligning):* The PAR scores were included as a matching criterion in this study for two reasons. Firstly, this score has a relationship with treatment complexity and secondly, this measure can be used to record the severity of malocclusion at any stage of treatment and thus provide a measure of quality of treatment.^{7,8} These scores were measured using PAR ruler. The PAR score was calculated prior to start of treatment on the study models of each patient. The differences between the scores were used to evaluate the efficiency of both the groups.
3. *Bracket bond failures:* Number of bracket bond failures in both groups was noted. Bond failures at the time of archwire placement and due to occlusal prematurities were not counted.
4. *Breakage of the brackets:* Breakages in the bracket wings, cap was evaluated in comparison with the ligating metal brackets.
5. *Staining of the SLBs:* The change in the color of the brackets was evaluated only in SLB group.

Questionnaire was used to evaluate patient’s comfort:

- Did the brackets cause discomfort or irritation to you?
- Did you feel embarrassing or uncomfortable to sport the braces in your mouth at social places?
- Did your friends easily notice the braces in your mouth?
- When your wires were changed did you feel any pain to your teeth after the appointment?
- Did you find that tooth brushing and oral hygiene was a greater confront?



Fig. 1A: Opal self-ligation brackets (Ultradent products, USA)




Fig. 1B: Manually ligating brackets (Nu-Edge, TP orthodontics, USA)

- Was your chairside appointment long or short?

Opal bracket cap opening: A gentle insertion of ‘Opal Key’ bracket opening instrument into the space between bracket base and closed bracket cap and rotation of the instrument handle lifts opens the cap (Fig. 4).

DISCUSSION AND RESULTS

A total of seven patients were examined in both the groups (SLB and MLB), for comparing the chairside time saved by the operator, comparing the bracket bond failures in both the groups, comparing the breakages with the wings and cap of the brackets and observe changes in the color of the brackets for staining.

The results of various parameters are presented as follows:

1. *Chairside time saving for archwire changes:* On placement of archwires it was found that SLBs was nearly (8.92) 9-fold less compared to the MLBs while on removal of archwires it was found that SLBs required only one-third the time taken by MLBs. It was found that overall procedure took 6.5 times less with SLBs (Graph 1).



Fig. 2: Orthosource phosphoric acid etchant (37%), python sealant and light cure composite paste

- These findings are in agreement with the studies done by Hanson, Damon, Majjer and Smith.^{3,5,9}
2. *Appliance efficiency (in leveling and aligning):* The mean and SD were calculated in both the groups for the pre- [mean: 22.8571 ± 7.0102 (SLB) and 19.0000 ± 5.0662 (MLB)] and post-treatment [mean: 9.4286 ± 4.1173 (SLB) and 8.0000 ± 2.4495 (MLB)] percentage reductions in PAR scores after a period of 120 days of the leveling and aligning stage. Paired Students t-test was used at 0.01% level to determine statistical significance of percentage reductions in PAR scores in SLB and MLB.

An unpaired Students t-test was done to find the statistical significant difference between the groups. The pretreatment (t = 1.1799 and p = 0.4455) as well as percentage reduction in PAR scores (t = 1.0251 and p = 0.3255) of SLB and MLB groups at 5% level revealed no statistically difference between both the groups (Graph 2).


Our findings are in agreement with Dobrin who has shown that conventional plastic brackets have poor efficiency due to their deformation.¹⁰ Dobrin showed conventional plastic brackets have poor efficiency due to their deformation. But they are not in concurrence with the studies by Damon, Eberting, Straja and Tuncay and Harradine.

The efficiency of metal SLBs is better than the plastic SLBs as the latter could fail:

- Rigidity,
 - Wear resistance of the tab on the cap which secures the wire into slot, and
 - Secure locking of the cap into its right place.
3. *Patients comfort:* The 6-question survey was done. Unpaired Student’s t-test (Graphs 3 and 4).

- a. Did the brackets cause discomfort or irritation to you?

A higher percentage of discomfort was noticed in MLB group than in SLB group.



Figs 3A to C: (A) Opal bond, (B) Opal prime and (C) Opal ultra etch

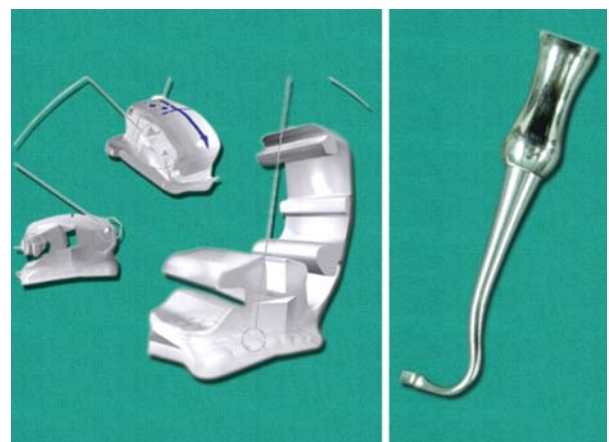

Fig. 4: Opal bracket cap opening

Not significant statistically. It suggests that equally comfortable to the patients, similar findings were reported by Eberting, Straja and Tuncay.¹¹

- b. Did you feel embarrassing or uncomfortable to sport the braces in your mouth at social places?

Equal response was seen, equally less embarrassing contrary to general perception that ‘a patient will be more uncomfortable wearing metal brackets than esthetic brackets.’ This was so MLB group were esthetically not much concerned and were mentally prepared to wear such brackets.

- c. Did your friends easily notice the braces in your mouth? MLB group perceived their brackets visible whereas 57.14% in SLB group felt so, statistically significant ($t = 2.8284$ and $p = 0.0152$). The obvious rationale was MLBs having metallic color whereas SLBs having translucency hindered visibility.
- d. When your wires were changed did you feel any pain to your teeth after the appointment?

Archwire changes elicited pain in majority of patients in MLB group (85.71%) and to a lesser percentage in the SLB group (57.1%).




Fig. 5: Opal SLBs, prior to usage (left), after 120 days of treatment (right)

Not statistically significant ($t = 1.1547$ and $p = 0.2707$), indicating both the bracket systems cause pain on engagement of archwire.

This finding compares favorably with the observations of Eberting, Straja and Tuncay.¹¹

- e. Did you find that tooth brushing and oral hygiene was a greater comfort?

A total of 85.71% in MLB group were comfortable whereas 28.57% in SLB group were at ease in maintaining the oral hygiene, statistically significant ($t = -2.4495$ and $p = 0.0306$).

The difference could be due to the fact that SLBs are large, have complex design and made of color absorbing plastic.

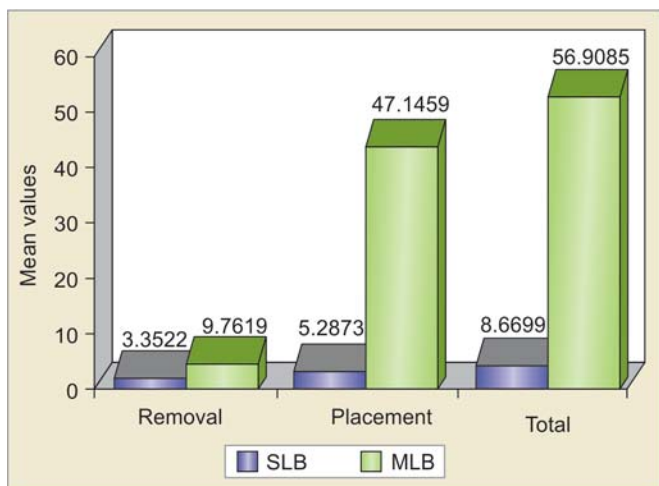
- f. Was your chairside appointment long or short? SLB group felt shorter appointment while MLB group thought it was longer, statistically highly significant ($t = -2.4495$ and $p = 0.0306$).

A 6.5-fold loss was seen in the chairside time for the MLB group.

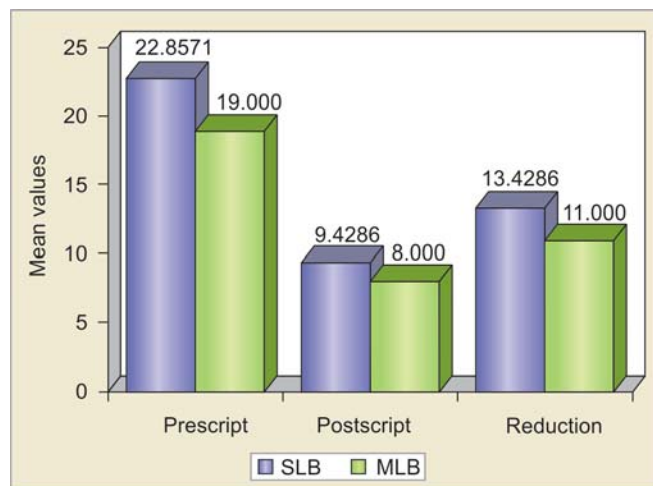
- 4. *Bracket bond failures:* No statistical analysis performed was performed. No bond failures were seen in MLB group while 22 bond failures in SLB group were seen. Failures were at the bracket and resin interface. Poor strength was seen due to:

- a. Inability of the primer to bond chemically with the base
- b. Poor design of the bracket base which does not provide sufficient mechanical locking for the adhesive.

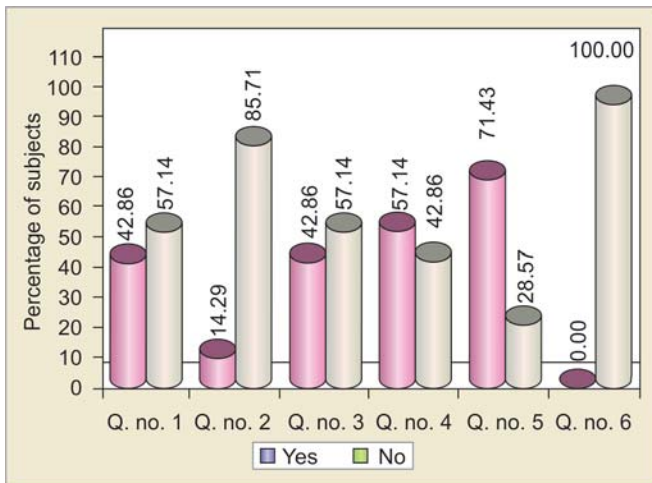
- 5. *Breakage of bracket:* No statistical analysis—no bracket breakage in the MLB group. Single cap breakage was noted in SLB group, which could be of significance as this is one in 138 brackets used. The inferior fracture resistances of plastic brackets could have lead for single cap breakage.



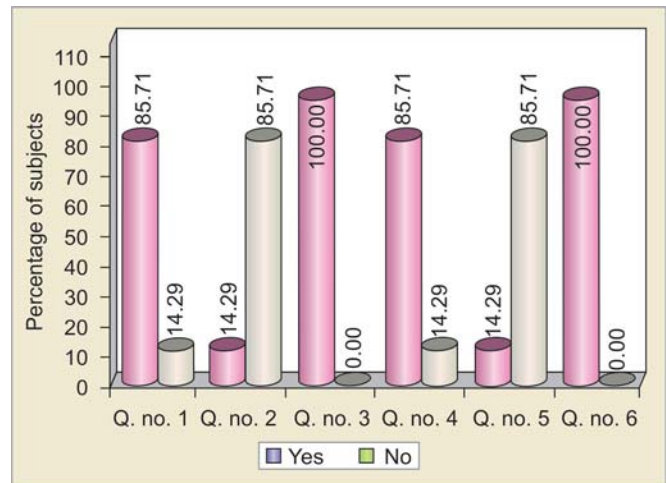
Graph 1: Comparison of both the groups with respect to chairside time saving in removal, placement and its total



Graph 2: Comparison of mean values of PAR scores in both the groups for pre-, post-treatment and in the reduction of PAR scores



Graph 3: Percentage distribution of response of study subjects according to different questions in SLB



Graph 4: Percentage distribution of response of study subjects according to different questions in MLB

6. *Staining of the brackets:* Color change was seen from translucent white to opalescent yellow in all the SLBs. Due to poor wear resistance of plastic bracket materials (Zinelis), after the cap is closed there is some space between the slot and the cap. The food debris and other staining elements trapped in this space (Fig. 5).

CONCLUSION

The following conclusions were drawn from the study:

1. SLBs were 6.5 times quicker than the MLBs during the archwire changes, thus saving considerable chairside time.
2. Treatment outcome after 120 days, in both groups was almost the same.
3. The SLBs had many bracket bond failures while MLBs had none.
4. SLBs had other shortcomings, such as bracket breakage, staining, cap opening, etc.

REFERENCES

1. Berger JL. Self-ligation in the year 2000. *J Clin Orthod* 2000;34:74-81.
2. Wildman AJ, et al. Round table: The Edgelok bracket. *J Clin Orthod* 1972;6:613-23.
3. Hanson GH. The SPEED system: A report on the development of a new edgewise appliance. *Am J Orthod* 1980;78:243-65.
4. Heiser W. Time: A new orthodontic philosophy. *J Clin Orthod* 1998;32:44-53.
5. Damon DH. The Damon low friction bracket: A biologically compatible straight wire system. *J Clin Orthod* 1998;35:670-80.
6. Damon DH. The rationale, evolution and clinical application of the self-ligating bracket. *Clin Orthod Res* 1998;1:52-61.
7. Richmond S, et al. The development of the PAR index [peer assessment rating]: Reliability and validity. *Eur J Orthod* 1992;14:125-40.

8. Richmond S, et al. The PAR index [peer assessment rating]: Methods to determine the outcome of orthodontic treatment in terms of improvement and standards. *Eur J Orthod* 1992;14:180-87.
9. Maijer R, Smith DC. Time savings with self-ligating brackets. *J Clin Orthod* 1990;24:29-31.
10. Dobrin RJ, Kamel IL, Musich DR. Load deformation characteristics of polycarbonate orthodontic brackets. *Am J Orthod* 1975;67:24-33.
11. Eberting JJ, Straja SR, Tuncay OC. Treatment time, outcome and patient satisfaction comparisons of Damon and conventional brackets. *Clin Orthod Res* 2001;4:228-34.

ABOUT THE AUTHORS

Shashank Sharad Gaiwad (Corresponding Author)

Senior Lecturer, Department of Orthodontics, MGM Dental College and Hospital, Navi Mumbai, Maharashtra, India, e-mail: drshashankgaiwad@yahoo.co.in

Ashwin Deshpande

Reader, Hazaribag College of Dental Sciences and Hospital, Hazaribag Jharkhand, India

Sachin S Doshi

Senior Lecturer, Department of Orthodontics, MGM Dental College and Hospital, Navi Mumbai, Maharashtra, India

Amol Mhatre

Senior Lecturer, Department of Orthodontics, MGM Dental College and Hospital, Navi Mumbai, Maharashtra, India

Manish Sonawane

Senior Lecturer, Department of Orthodontics, MGM Dental College and Hospital, Navi Mumbai, Maharashtra, India

Caries Status of Children and Oral Health Behavior, Knowledge and Attitude of Their Mothers and Schoolteachers in Mathura City

Ramen Haloi, Navin Anand Ingle, Navpreet Kaur

ABSTRACT

Aim: The study was undertaken to assess the caries status in children of 1st (6 years) and 6th grade (12 years) and knowledge, attitude and practice (KAP) of mothers and schoolteachers in Mathura city.

Materials and methods: A total of 872 mothers, 140 schoolteachers, 500 children of grade I and 500 children of grade VI participated in the study. Clinical examinations of grades I and grade VI children were performed. Data on mothers and teachers were collected through personal interviews and self-administered questionnaires respectively. Statistical significance was set at $p \leq 0.05$.

Results: At the age of 6 and 12, the mean decayed, missing and filled teeth (DMFT) index was 2.4 and 1.3 respectively. Mothers showed a fair level of knowledge (74.9%) and favorable attitude (70.6%), while maximum schoolteachers showed a good level of knowledge (67.9%) and favorable attitude (57.1%) toward oral health. Schoolteachers, dentists and television were found to be the most important source of dental health information among the schoolteachers and mothers.

Conclusion: It is concluded from the study that oral health knowledge of mothers and teachers were found to be fair and good respectively. The schoolteachers knew about the poor dental conditions in children and wanted to become involved in oral health education. Training of the teachers should aim at improving their level of knowledge on oral health.

Keywords: Knowledge, Attitude, Oral health behavior, Dental caries.

How to cite this article: Haloi R, Ingle NA, Kaur N. Caries Status of Children and Oral Health Behavior, Knowledge and Attitude of Their Mothers and Schoolteachers in Mathura City. *J Contemp Dent* 2012;2(3):78-83.

Source of support: Nil

Conflict of interest: None declared

INTRODUCTION

Many industrialized countries have experienced a decline in dental caries prevalence among children over the past decades.^{1,2} Against this, increasing levels of dental caries have been found in some developing countries, especially for those countries where preventive programs have not been established.³⁻⁵ In order to control the growing burden of oral diseases, a number of developing countries recently introduced school-based oral health education and preventive programs which aim at improving oral health behavior and status of the child population.^{6,7}

India, a developing country, faces many challenges in rendering oral health needs. The majority of Indian population resides in rural areas, of which more than 40% constitute children. These children cannot avail dental facilities due to inaccessibility, financial constraints and stagnation of public dental health care services. This entails the health professional to adopt a more practical approach to achieve prevention of oral diseases.^{8,9}

To promote oral health, oral health education for children is considered a priority because of the caries high risk at this age, as well as the constant changes in oral environment, the facility for changing bad habits and provision of higher facility for learning. Educating the children, because of its coverage, is important for the concretization of health promotion actions directed to the improvement in children's skills, for making decision favorable to community, for the creation of healthy environment and consolidation of public politics for the quality of life.¹⁰

Schoolteachers and parents, especially mothers, are considered to be an important target group for various health educational activities with the underlying objective of inculcating healthy lifestyle practices into children for a lifetime.⁹ Schoolchildren in their early years involve 'Primary socialization' during which the earliest childhood routines and habits are acquired.^{11,12} These include dietary habits and healthy behaviors established as norms in the home and are dependent on the knowledge and behavior of parents and elder siblings. Studies have reported that poor attitude of parents toward oral health of young children are associated with increased caries prevalence.^{12,13} On the contrary, studies have also shown that the more positive is the parents' attitudes toward dentistry the better will be the dental health of their children.¹²⁻¹⁴

By virtue of their training and opportunity to influence large numbers of children and their parents, teachers form a group of particular interest in the planning and implementation of oral health preventive programs.¹⁵ Increasing the oral health knowledge of primary schoolteachers provide an opportunity to educate their students that has access to large populations of young people. Teachers cannot assist in developing well-informed students, if they themselves remain misinformed. Thus, the schoolteachers need to be enabled for the task in terms of

improving their deficient knowledge on oral health and relative effectiveness of measure to prevent various oral problems.¹⁶ Inadequate knowledge, skills and motivation for teachers and mothers to provide oral health education has shown unfavorable repercussions on children's oral health.¹⁷ A very few literatures and records were found which shows the influence of teachers and mothers oral health behavior, knowledge and attitude on their children's dental caries status. Keeping all these points in view, a study was undertaken to assess the caries status of children and oral health behavior, knowledge and attitude on their mothers and schoolteachers in Mathura city.

AIMS AND OBJECTIVES

1. To assess the caries status of 1st (6 years) and 6th grade (12 years) schoolchildren.
2. To assess the oral health behavior, knowledge and attitude of their mothers and schoolteachers.
3. To determine the source of information regarding oral health of mothers and schoolteachers.
4. To assess the health-promoting role of schoolteachers.

MATERIALS AND METHODS

An epidemiologic survey was conducted to assess the caries status in children of 1st (6 years) and 6th grade (12 years) and oral health behaviors, knowledge and attitude of mothers and schoolteachers in Mathura city.

Source of Data

According to the list obtained from Basic Shiksha Adhikaari office, there were a total of 7,000 schoolchildren of grade I and grade VI among the 125 private schools present in Mathura city.¹⁸ Prior to the survey informed consent was obtained from each study subjects. Data was collected through a clinical examination of schoolchildren of grade I (6 years) and grade VI (12 years) of private schools of Mathura city. Moreover, the study comprised the mothers of the schoolchildren ($n = 872$, 86.3% response rate) who responded to a structured interviews. Finally, the study comprised the teachers of the 20 private schools and the total of 140 schoolteachers (response rate 100%) responded to self-administered questionnaire.

Inclusion Criterion

- All the available schoolchildren of 20 private schools of Mathura city who were in grade I (6 years) and grade VI (12 years) were included in our study.
- Mothers and schoolteachers of the grade I (6 years) and grade VI (12 years) who were in the age range of 15 to 64 years and willing to participate in the survey.

Exclusion Criterion

- Subjects not willing to participate in the survey and those who were absent on the day of examination.
- Subjects suffering from major systemic illness.

Sampling Methodology

Based on the prevalence obtained for dental caries in children of age 6 to 12 years, it was necessary to take 925 as the minimum sample size. A slightly higher sample size of 1,000 was selected to compensate for any kind of permissible error and to increase the accuracy of the study. Mathura city was divided into five geographical zones—central, North, South, East and West. In order to cover the total sample size of 1,000, 200 schoolchildren from each of the five zones were randomly selected out of which 100 children were from grade I (6 years) and 100 children were from grade VI (12 years). A total of 20 private schools participated in the study.

Mothers of all 1,000 schoolchildren were asked to attend a structured interview. A total of 872 mothers (response rate 86.3%) responded to structured interviews. All interviews were undertaken in the schools, and the mothers were not informed about the professional background of the interviewer. The questions concerned oral health knowledge, attitudes, sources of oral health information, oral health behavior of the child and mother, parental support in oral health, evaluation of the dental health of their child, number of children in the family and educational level of the parents. Oral health knowledge and attitudes were measured by using positive and negative responses and 5-point Likert scale to the loaded statements. The validity and the reliability of the items have been tested in a previous methodologic study.¹⁹

From those 20 private schools, a total of 140 schoolteachers responded to self-administered questionnaires (response rate 100%). Identical structured questions on knowledge and attitudes were given to teachers and mothers but in case of schoolteachers additional structured questions were added related to their role in health promotion.

Statistical Analysis

The collected data was entered in the Microsoft excel sheet and analyzed using the SPSS, version 17.0 statistical package. Level of significance (p-value) was fixed at 0.05%. The χ^2 test was applied for the statistical evaluation of proportions and Student's t-tests were performed for the comparison of means.

RESULTS

The results of the study have been depicted in Figures 1 to 4 and Tables 1 to 4.

Most of the study subjects of both schoolteachers and mothers were distributed in the age group of 31 to 40 years (Fig. 1). The source of dental health information for schoolteachers and mothers are illustrated in Figure 2.

Dental Caries

The mean caries experience is given in Table 1 and it is shown that the d/D component constituted most of the caries indices. No significant differences in the caries indices were found by sex, however, the figures were higher in males than females in grade I. On the other hand the mean caries experience of the females were higher as compared to males of grade VI children ($p < 0.05$). Table 2 presents the distribution of children by absolute value of caries index according to school grade, and Table 3 shows the distribution of children by caries severity zones.

Knowledge and Attitudes of Mothers

Maximum mothers, i.e. 74.9% showed fair knowledge followed by a portion, i.e. 25% showed good knowledge regarding oral health. A significant proportion of mothers, i.e. 70.6% showed favorable attitude toward oral health (Figs 3 and 4). Oral health knowledge of mothers has been correlated with level of education, age and number of children, a highly statistically significant correlation was found between oral health knowledge of mothers with all the three variables mentioned above (p-value is 0.000).

Knowledge and Attitudes of Schoolteachers

Maximum schoolteachers, i.e. 67.9% showed good knowledge followed by a portion, i.e. 32.1% showed fair knowledge regarding oral health. A significant proportion of schoolteachers, i.e. 57.1 and 42.9% of the schoolteachers showed favorable and most favorable attitudes toward oral health (Figs 3 and 4). A highly statistically significant correlation was found between oral health knowledge and gender (p-value is 0.000). No statistically significant relation was found when oral health knowledge was compared with level of education (p-value is 0.74). When attitudes of the schoolteachers were correlated with level of education and gender, a highly significant correlation was found between gender and attitude of the schoolteachers (p-value is 0.000).

Oral Health Habits

Maximum number of study subjects both from schoolteachers and mothers, i.e. 64.3 and 47.6% respectively had visited the dentist whenever they had dental problems. Almost equal proportion of study subjects from both the

groups had seen a dentist within the past 12 months. All the schoolteachers, i.e.100% revealed that they brushed their teeth with toothbrush and toothpaste, while 99.5% of mothers revealed the same. A significant proportion, i.e. 72% of mothers brushed once daily while maximum schoolteachers answered that they brushed their teeth at least twice a day.

Role of Teachers in Promoting Oral Health

Respondents were asked to indicate the extent of their agreement or disagreement with statements of responsibilities that are sometimes expected of schoolteachers. A scale ranging from strongly agree to strongly disagree was used and then collapsed to agree/disagree. Respondents were most likely to accept responsibility for roles that did not involve loss of class time by students, out of school efforts, or direct supervision. In particular, the latter category was

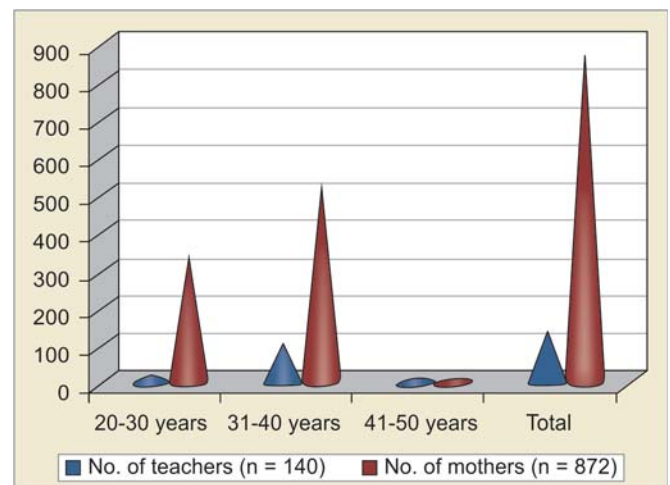


Fig. 1: Distribution of the study subjects according to age among schoolteachers and mothers

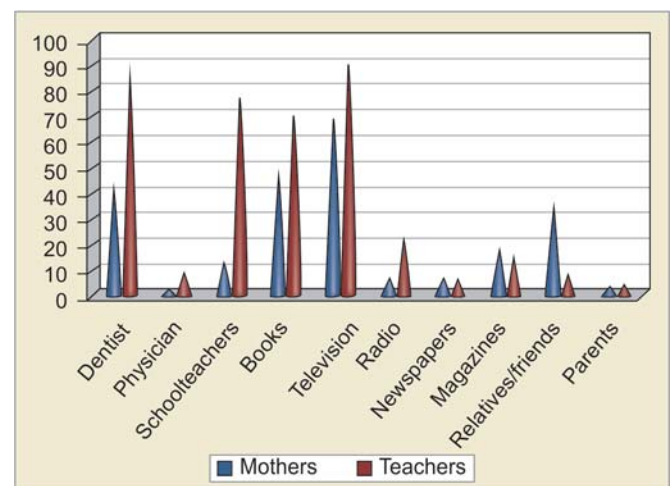


Fig. 2: Distribution of the study subjects according to source of dental health information

not considered by respondents to be a responsibility of teachers (Table 4).

DISCUSSION

The interview method was chosen for the study of the mothers since, many of these were not familiar with the questionnaire surveys. Due to practical and economical reasons the data on the schoolteachers were collected by means of self-administered questionnaires. Acceptable response rates were obtained for both data sets. In order to control the reliability, highly structured questionnaires were created and the wording of the questions to mothers and teachers was identical to ensure valid comparisons of the responses. Besides the pilot study, the methodology of the questionnaires had been assessed in previous studies.¹⁹

Source of Dental Health Information of Mothers and Schoolteachers

In our study, television, dentist and schoolteachers were found to be the most frequently reported source of dental health information among both mothers and schoolteachers.

These results were in accordance with the previous studies conducted by Petersen et al,⁵ Elena et al,²⁰ Lang et al.²¹

Caries Status of Schoolchildren

This study showed that at the age of 6 and 12, the mean decayed, missing and filled teeth (dmft/DMFT) index was 2.4 and 1.3 respectively. These findings were in agreement with previous surveys of 12-year-old which had shown the mean DMFT at 1.1 to 1.9.²²⁻²⁵ Our study results were much lower than a previous study conducted by Bondarik Elena, they had found a mean DMFT of 2.7 in 12 years old children in Belarus.²⁰

Dental Knowledge of Mothers and Schoolteachers

The knowledge regarding oral health of mothers and schoolteachers seemed to be diffused. On the one hand, significant proportions of the mothers knew about the role of bacteria and sugar in dental caries, on the other hand, the level of knowledge was low with regard to the effect of hidden sugar and fluoride. These study results were in

Table 1: Dental caries experience of grade I and grade VI children according to gender

Dental caries index	Grade I (n = 500)		Grade VI (n = 500)	
	Male	Female	Male	Female
Decayed (d)	3.3	2.59	–	–
Missing (m)	0.02	0.02	–	–
Filled (f)	0.02	0.02	–	–
Total DMFT	3.4	2.64	–	–
Decayed (D)	–	–	0.76	0.93
Missing (M)	–	–	0	0.05
Filled (F)	–	–	0.19	0.46
Total DMFT	–	–	0.96	1.45

Table 2: Distribution in percentage according to absolute value of dental caries index by school grade/age

Grade	Sex	0	1-4	5-8	9-12
I (primary teeth)	Male	18.8%	54.4%	24.4%	2.4%
	Female	26%	56.8%	15.6%	1.6%
VI (permanent teeth)	Male	67.1%	29.7%	3.2%	0
	Female	43.9%	56.1%	0	0

Table 3: Distribution in percentage by caries severity zones according to grade/age

Caries severity zones	6 years (primary teeth)		12 years (permanent teeth)	
	Male	Female	Male	Female
Zone 1 (caries free)	18.8%	26%	67.1%	43.9%
Zone 2 (caries in pits/fissures in molars/premolars)	5.2%	8.7%	21.5%	40.5%
Zone 3 (caries in approximal surfaces of canines/premolars/molars)	18.1%	20.3%	2.1%	4.2%
Zones 4 (caries in incisors and/or smooth surfaces)	57.9%	45%	9.3%	11.4%

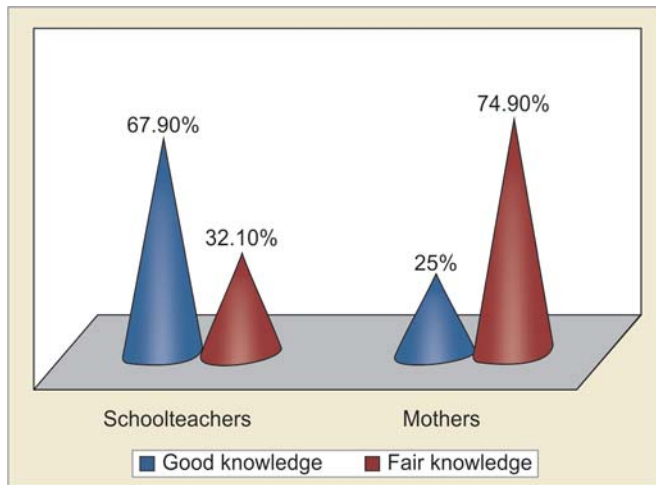


Fig. 3: Distribution of the study subjects according to knowledge score among schoolteachers and mothers

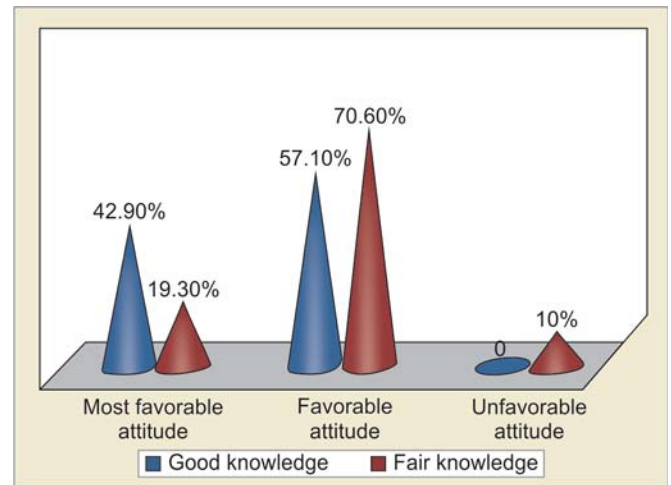


Fig. 4: Distribution of the study subjects according to attitude score among schoolteachers and mothers

Table 4: Perceived role of teachers in promoting oral health

Teachers should	Agree	Disagree
Should refer students with dental problems to the dentists	93.6%	6.4%
Advise students regarding advertising of commercial sugar products	72.9%	17.1%
Instruct students about scientifically valid methods to prevent oral diseases	88.6%	11.4%
Allow class time for students to get dental care	45%	55%
Be actively involved in community efforts to improve students' oral health	60%	40%
Supervise daily brushing and flossing in the classroom	12.1%	87.9%

accordance with the previous studies conducted by Petersen et al,⁵ Elena et al,²⁰ Lang et al.²¹

Attitudes Toward Oral Health of Mothers and Schoolteachers

Both the mothers and the schoolteachers showed positive attitudes toward prevention and the study indicates that various sources would seem available and effective for oral health information. Studies conducted by Ramen et al and Pankaj et al²⁶ had found that the majority of the study subjects had favorable attitude toward oral health which was in accordance with our study results.

Oral Health Behavior of Mothers and Schoolteachers

No significant difference in views was found between mothers and schoolteachers regarding oral health behaviors. The survey showed a clear discrepancy between dental knowledge and practice, which was in accordance with the previous studies conducted by Petersen et al,⁵ Elena et al,²⁰ and Lang et al.²¹

Health-promoting Role of Schoolteachers

Respondents were more likely to accept responsibility for roles that did not involve loss of class time by students, out-of-school efforts or direct supervision. In particular, the

latter category was not considered by respondents to be a responsibility of schoolteachers. This confirms the observation of other investigators.^{27,28}

However, the data collection methods may have certain limits. With respect to dental knowledge, oral hygiene habits and frequency of dental visits, over-reporting may be assumed whereas under-reporting has to be considered with regard to the consumption of sugar, sweets and sugary drinks.

CONCLUSION

The study concluded that there were no significant differences in the level of oral health knowledge between mothers and schoolteachers, even though the teachers tended to have been informed more often by dentists. Both mothers and schoolteachers showed positive attitudes toward prevention, and the study indicates that various sources would seem available and effective for oral health information. The results showed disparity between dental knowledge and oral health practices of both mothers and schoolteachers. The teachers responded positively to becoming involved in the oral health education of the children, and they can be undoubtedly become key persons in this activity. However, they need proper training and practical support from dentists experienced in public health, and the teachers should also be provided with educational materials. By providing suitable educational materials and

by engaging in health promotional activities, dental public health professionals can interact with schoolteachers in a mutually beneficial manner.

REFERENCES

- Marthaler TM, O'Mullane D, Vrbic V. The prevalence of dental caries in Europe 1990-95. *Caries Res* 1996;30:237-55.
- Burt BA. Trends in caries prevalence in North American children. *Int Dent J* 1994; 44:403-13.
- Sheiham A. Changing trends in dental caries. *Int J Epidemiol* 1984;13:142-47.
- Petersen PE, Razanamihaja N. Oral health status of children and adults in Madagascar. *Int Dent J* 1996;46:41-47.
- Petersen PE, Esheng Z. Dental caries and oral health behavior situation of children, mothers and schoolteachers in Wuhan, People's Republic of China. *Int Dent J* 1998;48:210-16.
- Petersen PE, et al. Effect of a school-based oral health education programme in Wuhan city, Peoples Republic of China. *Int Dent J* 2004;54:33-41.
- George B, John J, Saravanan S, Arumugham IM. Oral health knowledge, attitude and practices of schoolteachers in Chennai. *JIAPHD* 2010;15:85-90.
- Thomas S, Tandon S, Nair S. Effect of dental health education on the oral health status of a rural child population by involving target groups. *J Indian Soc Pedod Prev Dent* 2000 Sep;18(3): 115-25.
- Raj SM, Prasad KVV, Javali SB. Factors affecting the knowledge on prevention of oral diseases among schoolteachers of Dharwad city: A survey from India. *Webmed Central Dent* 2011;2(2):4-13.
- Garbin CAS, Garbin AJI, dos Santos KT, Lima DP. Oral health education in schools: Promoting health agents. *Int J Dent Hygiene* 2009;7:212-16.
- Holm AK. Caries in preschool children: International trends. *Int J Dent* 1990;18(6):291-95.
- Suresh BS. Mothers' knowledge about pre-school child's oral health. *JISPPD* 2010;28(4):282-87.
- Hinds K, Gregory JC. National diet and nutrition survey: Children aged 1½ to 4½ years. Vol 2: Report of dental survey. London: HMSO, 1995.
- Friedman LA, Mackler IG, Hoggard GJ. A comparison of perceived and actual needs of a selected group of children in Texas community. *Dent Oral Epidemiol* 1976;4:89-93.
- Astrom AN, Jackson W, Mwangosi IE. Knowledge, beliefs and behavior related to oral health among Tanzanian and Ugandan teachers trainees. *Acta Odontol Scand* 2000;58:11-18.
- Pai V, et al. Dental awareness among Kannada and English medium primary schoolteachers in Mangalore city. *JIAPHD* 2006;7:7-12.
- Mwangosi IE, Nyandindi U. Oral health related knowledge, behaviors, attitudes and self-assessed status of primary schoolteachers in Tanzania. *Int Dent J* 2002;52:130-36.
- Basic Shiksha Adhikari, Department of Education, Dholi Pyau, Mathura.
- Petersen PE. Guttman scale analysis of dental health knowledge and attitudes. *Comm Dent Oral Epidemiol* 1989;17:170-72.
- Elena B, Petr L. Oral health and children attitudes among mothers and schoolteachers in Belarus. *Stomatologija-Baltic Dent Maxillofacial J* 2004;6:40-43.
- Lang WP, Woolfolk MW, Faja BW. Dental health knowledge and attitudes of elementary schoolteachers in Michigan. *J Public Health Dent* 1989;49:44-50.
- Li G, Wang C, Li J, Ai Y. Dental caries in Yanan school-children aged 12 years: China. *Comm Dent Oral Epidemiol* 1989; 22:208.
- Hu DY, Liu DW. Trends of caries prevalence and experience in children in Chengdu City, West China, 1982-90. *Comm Dent Oral Epidemiol* 1992;20:308-09.
- Shi Y, Barmes D, Bratthall D, et al. WHO pathfinder caries survey in Beijing extended with data for prevalence of mutans streptococci. *Int Dent J* 1992;42:31-36.
- Petersen PE, Guang LX. Dental caries prevalence in a group of schoolchildren in Wuhan City, PR China. *Comm Dent Oral Epidemiol* 1994;22:465-66.
- Sehgal P, Ankola A, Nagesh L, Hegde P. Knowledge, attitude and practices towards oral health among Anganwadi workers of Belgaum city, Karnataka. *JIAPHD* 2005;5:14-16.
- Loupe MJ, Frazier PJ. Knowledge and attitudes of schoolteachers toward oral health programs and preventive dentistry. *J Am Dent Assoc* 1983 Aug;107:229-34.
- Boyer ME. Classroom teachers' perceived role in dental health education. *J Public Health Dent* 1976;36:237-43.

ABOUT THE AUTHORS

Ramen Haloi (Corresponding Author)

Postgraduate Student, Department of Public Health Dentistry KD Dental College and Hospital, Mathura, Uttar Pradesh, India
e-mail: drramenhaloi@gmail.com

Navin Anand Ingle

Professor and Head, Department of Public Health Dentistry, KD Dental College and Hospital, Mathura, Uttar Pradesh, India

Navpreet Kaur

Senior Lecturer, Department of Public Health Dentistry, KD Dental College and Hospital, Mathura, Uttar Pradesh, India

Cone Beam Computed Tomography: Adding the Third Dimension

Neha Anil Patil, Rohit Gadda, Rohini Salvi

ABSTRACT

Cone beam computed tomography is a comparatively new three-dimensional imaging technology, which has been specially developed for imaging of the maxillofacial complex. The aim of this paper is to accustom the dental fraternity with the wide and potential applications of cone beam computed tomography in dentistry.

Keywords: Cone beam computed tomography, Impacted teeth, Dental implants, Endodontics.

How to cite this article: Patil NA, Gadda R, Salvi R. Cone Beam Computed Tomography: Adding the Third Dimension. *J Contemp Dent* 2012;2(3):84-88.

Source of support: Nil

Conflict of interest: None declared

INTRODUCTION

Radiology is an important diagnostic tool and selection and application of an appropriate technique helps the dental practitioner arrive at a correct diagnosis. The conventional two-dimensional (2D) intraoral and extraoral radiographic procedures, though very routinely used for evaluation of dental or maxillofacial complex, suffer from several limitations. These limitations are magnification, distortion, superimposition and misrepresentation of structures.¹⁻³ With the introduction of cone beam computed tomography (CBCT) in 1997^{4,5} imaging the maxillofacial region has become much more accurate and the diagnosis much more precise.

Most of us are familiar with the thin slices which are produced by a helical fan-beam CT also known as medical computed tomography (MDCT), but CBCT allows the creation in 'real-time' of images not only in the axial plane

but also 2D images in the coronal, sagittal and even oblique or curved image planes—a process referred to as multiplanar reformation (MPR). In addition, CBCT data are amenable to reformation in a volume, rather than a slice, providing three-dimensional (3D) information (Table 1).²

CBCT TECHNOLOGY

The capturing of an image in CBCT scanner involves a single 360° rotation of the X-ray source and a reciprocating area detector in synchronization around the patient's head. At certain degree intervals, single projection images, known as 'basis' images, are captured. These are similar to lateral cephalometric radiographic images, each slightly offset from one another. Software programs which have many refined algorithms use these basis projection images to generate a 3D volumetric data further from which different images in axial, coronal and sagittal planes can be reconstructed.²

APPLICATIONS OF CBCT

Oral and Maxillofacial Surgery

1. *Impacted teeth:* CBCT is of great use in assessing the exact position of an impacted or a supernumerary tooth and its relation to the surrounding vital structures. Most commonly impacted teeth are the mandibular third molars. While planning a disimpaction, knowledge about the relation of the tooth to the inferior alveolar nerve canal is of prime importance to avoid any intraoperative or permanent untoward complication. CBCT enables us to assess the exact relation of the tooth to the canal, giving us information of the location of the canal whether buccal/lingual in relation to the tooth and also the

Table 1: Comparison of MDCT with CBCT³

Point of comparison	CBCT	MDCT
Shape of the beam	Cone beam	Fan-shaped beam
Cost	Three to 5 times less than MDCT	Costly
Size of the equipment	Substantially lighter and smaller	Heavier and bigger in size
Radiation dose	Low (68 micro Sv)	High (600 micro Sv)
Resolution	Due to smaller pixel size better resolution	Resolution is less as compared to CBCT
Scan time	Faster scan	Long scan time as compared to CBCT
Patient position	Sitting/standing	Lying down
Patient convenience	The open design of the equipment along with short scan times and upright position enhances the patient convenience and acceptance	Patient can experience claustrophobia due to closed design of the gantry

proximity of the canal to it. CBCT examination also helps the dental practitioner know the exact number of roots of the tooth planned for extraction their precise position, presence of any dilacerations and analysis of the extent of the pathology related to them, allowing for a defined treatment plan, which would result in less invasive surgical intervention (Fig. 1).^{2,4-6}

2. *Trauma cases:* Another frequent application of CBCT is in assessing fractures of the maxillofacial complex. The conventional 2D imaging has a number of limitations is assessing the exact location and extent of the fracture line, one of the major being superimpositions of the surrounding structures. Though MDCT gives accurate information but the radiation dose to the patient

involved during the scan is reasonably high as is the duration of the scan and the cost. On the contrary, CBCT scanning involves low radiation dose, easy positioning of the patient, short scan time and low cost, thus increasing the patient acceptance. The resolution of the resulting CBCT images is also higher as compared to the MDCT image (Fig. 2).

3. *Orthognathic surgery planning:* CBCT is also largely used in planning orthognathic surgery which requires detailed visualization of the interocclusal relationship in order to augment the 3D virtual skull model with a detailed dental surface.⁷

4. *Calcified structures in salivary glands:* The maximum intensity projection (MIP) images provides valuable information on the distribution and location of soft tissue or vascular calcifications like tonsilloliths, salivary gland stones, calcified lymph nodes and carotid artery calcifications. As the voxel gray scale intensity of these calcified areas is higher than the neighboring voxels, they appear as bright spots on MIP images (Fig. 3).

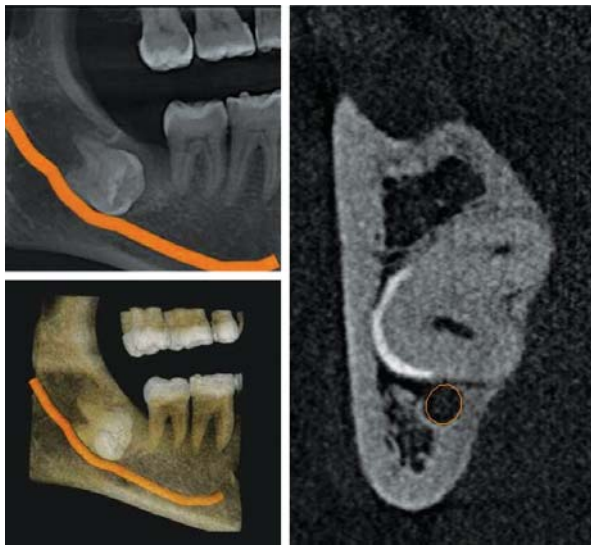


Fig. 1: CBCT images of impacted 48. Reconstructed panoramic image and 3D reconstruction showing horizontally impacted 38 in close approximation to the inferior alveolar nerve canal. Cross section showing the nerve canal is inferior in relation to 38

PERIODONTICS

CBCT is an accurate tool in assessing the morphologic condition of bone.^{8,9} Many studies have proved that the measurements as performed on the CBCT were at par with the ones done by a periodontal probe.^{8,10} As discussed earlier the superimposition of the surrounding structures as seen on conventional 2D radiographs, hinders the assessment of furcation involvements. On the other hand CBCT specifically helps the periodontist to detect furcation bone loss, buccal lingual defects, fenestrations, dehiscence along with accurate measurement of intra bony defects and evaluate outcome of regenerative periodontal therapy (Fig. 4).^{8,10,11}

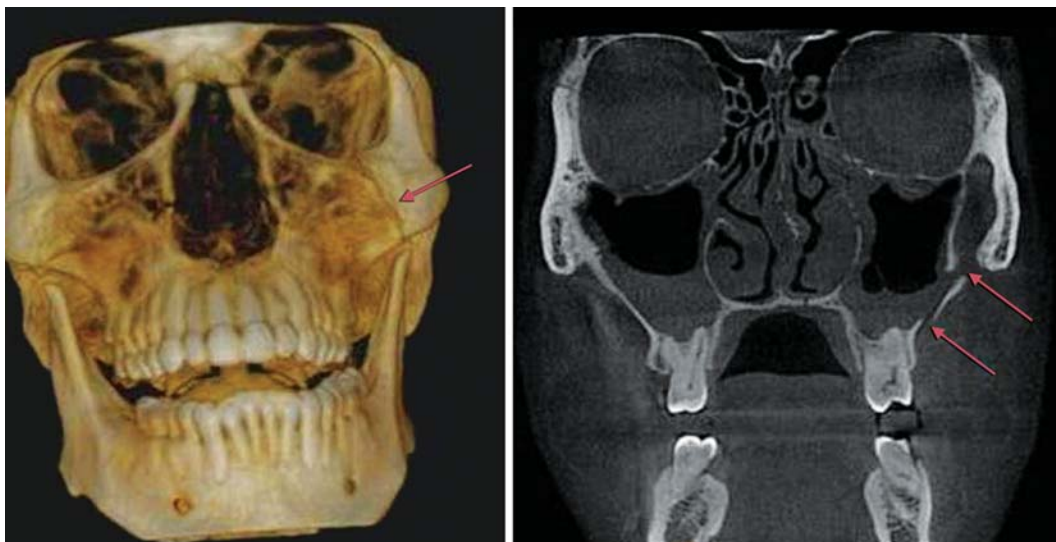


Fig. 2: 3D reconstruction and the coronal section is showing discontinuity suggestive of fracture in relation to the posterolateral wall of the left maxillary sinus

ENDODONTICS

An important advantage of CBCT in endodontics is demonstration of anatomic features in 3Ds (axial, coronal, sagittal) which the routine intraoral and panoramic projections cannot. Image enhancement algorithms like zoom magnification, window/level adjustments, and text or arrow annotation can be applied and the cursor-driven measurement algorithms that make possible real-time dimensional assessment which are free from distortion and magnification (Fig. 5).¹²

The applications can be summarized as below:¹²

- Assessing number of root canals and their curvature.
- Diagnosis of dental periapical pathosis.
- Intra- or postoperative assessment of endodontic treatment complications, such as overextended root canal obturation material, separated endodontic instruments, calcified canal identification and localization of perforations.
- Diagnosis and management of dentoalveolar trauma, especially root fractures, luxation and/or displacement of teeth and alveolar fractures.
- Localization and differentiation of external from internal root resorption or invasive cervical resorption from other conditions, and the determination of appropriate treatment and prognosis.

- Presurgical case planning to determine the exact location of root apex/apices and to evaluate the proximity of adjacent anatomical structures.

IMPLANTOLOGY

MDCT has long been used for measuring the precise height and width of bone for placement of implants. However, the ability of CBCT to provide greater accuracy in measurements at lower radiation doses has made it the preferred option in implant dentistry.^{13,14} The CBCT software does not only allow for measurements of the bone quantity but also helps to measure bone quality¹⁵⁻¹⁷ along with algorithms with help virtual implant placement. Also there are softwares to construct surgical guides which will further reduce the failure rate.^{13,18,19} CBCT is also used for bone graft assessment and evaluation of post-treatment cases (Fig. 6).^{5,20}

ORTHODONTICS

CBCT offers a number of advantages for imaging in orthodontics. To list some:²¹⁻²³

- Tooth position and localization
- Measuring bone dimensions for mini-implant placement
- Rapid maxillary expansion

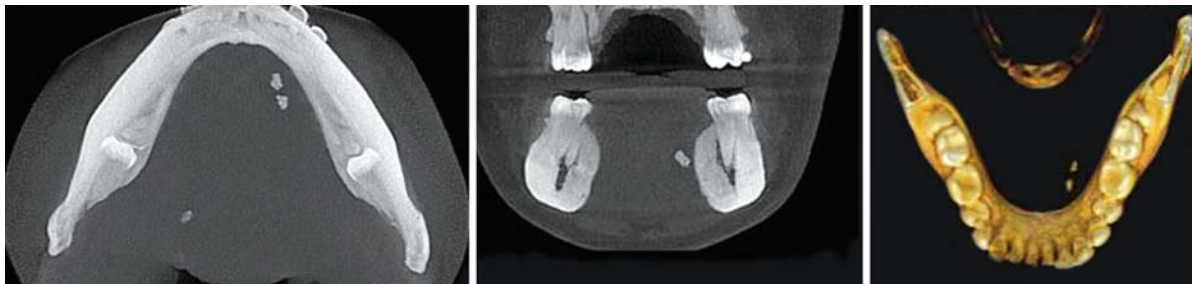

Fig. 3: Axial and coronal sections with 3D reconstructed image show two well-defined structures in the submandibular region suggestive of calcification in the submandibular gland

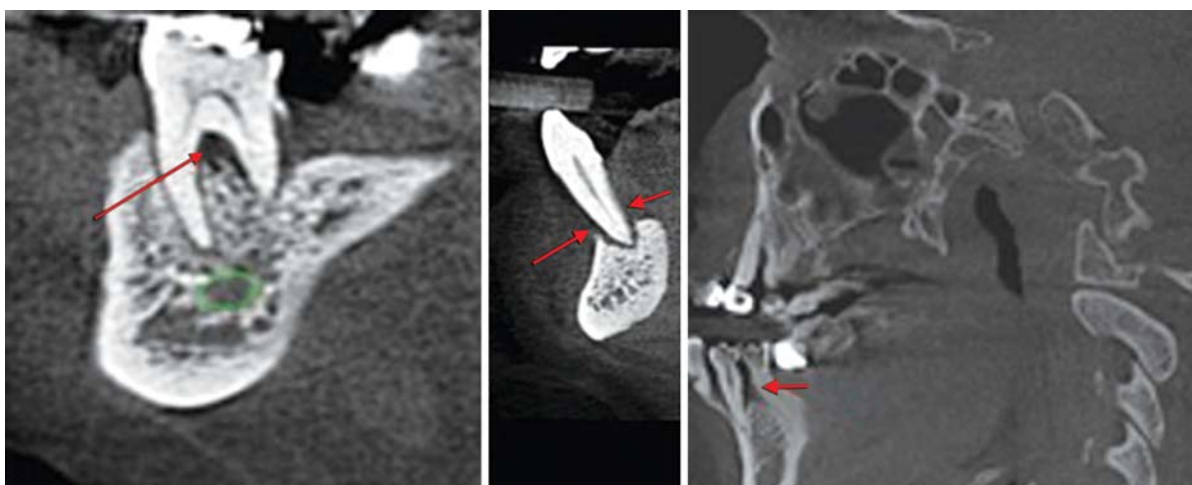


Fig. 4: Clockwise from top: Sagittal section of 38 showing bone loss in the furcation area, cross section of mandibular anterior region showing loss of labial and lingual cortical plates, sagittal section showing interdentary bone loss in mandibular premolar area

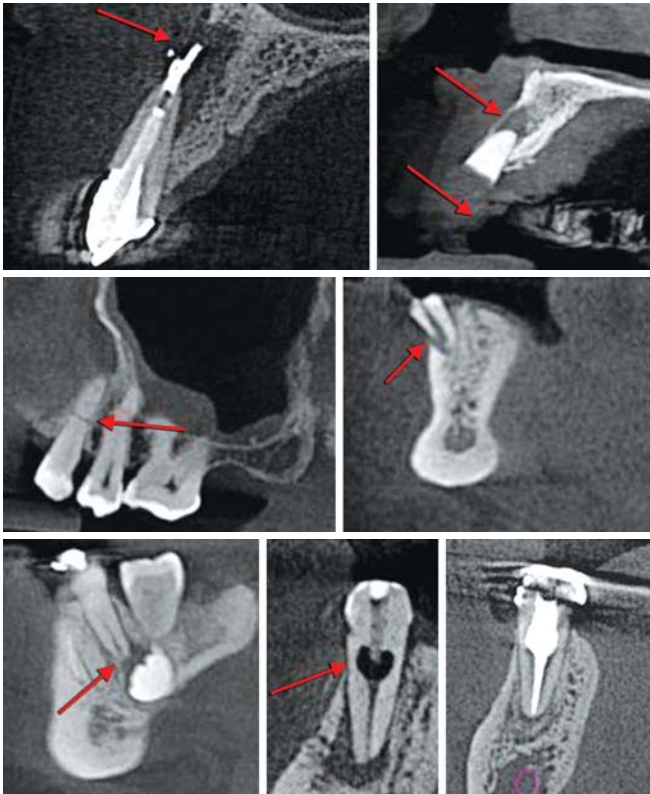


Fig. 5: Clockwise from top: Cross sections showing overextended root canal filling material with a periapical area of very low density suggestive of a periapical pathology, root piece with a periapical pathology, horizontal root fracture of the first premolar, vertical root fracture of canine, external resorption of the distal root of 36, internal resorption seen in 34, 34 postendodontic treatment

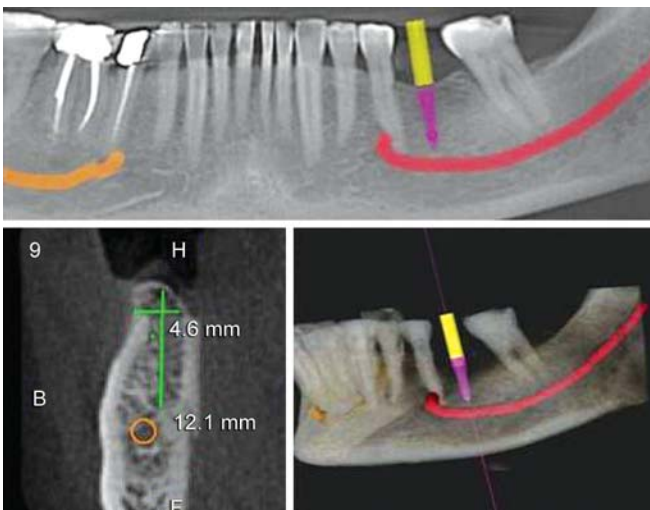


Fig. 6: Reconstructed panoramic and 3D image showing virtual implant placement. Cross section showing height and width of the bone in this region

- 3D cephalometry
- Airway assessment
- Age assessment
- Orthognathic surgery.

As craniofacial anatomy is precisely described, this meticulous information provided about the anatomical

relationships which helps tremendously in better diagnosis, treatment and prognostication.²⁴

BONE PATHOLOGIES

Cysts, tumors and other bony lesions though detected on conventional radiographs, CBCT makes available information pertaining to the actual size of the lesion, its relationship with the surrounding anatomic landmarks and extension of the lesion into paranasal sinuses, orbital cavities, nasopharynx, skull, etc. This added information provided by CBCT images goes ahead in a more accurate diagnosis between inflammatory lesions of the jaws, cysts, odontogenic tumors, nonodontogenic tumors, some other benign conditions like fibrous dysplasia, thalassemia, and even malignant lesions like squamous cell carcinoma, metastatic tumors, osteosarcoma, mucoepidermoid carcinoma, malignant lymphoma, Ewing sarcoma.^{25,26}

CONCLUSION

CBCT provides us with images with have high diagnostic quality with relatively short scanning times (10-70 seconds) and at a low radiation dose, thus finding application in all the dental specialties. To maximize the clinical output further the CBCT data should undergo a thorough clinical evaluation.

ACKNOWLEDGMENT

The authors gratefully acknowledge ScanDENT Imaging Centre, Matunga, Mumbai, for providing CBCT data for all the figures.

REFERENCES

1. Calhoun PS, Kuszyk BS, Heath DG, et al. Three-dimensional volume rendering of spiral CT data: Theory and method. *Radiographics* 1999;19:745-64.
2. Scarfe WC, Farman AG, Sukovic P. Clinical applications of cone-beam computed tomography in dental practice. *J Can Dent Assoc* 2006;72(1):75-80.
3. Macleod I, Heath N. Cone beam computed tomography (CBCT) in dental practice. *Dent Update* 2008;35:590-98.
4. Radiation protection: Cone beam CT for dental and maxillofacial radiology. Provisional guidelines 2009 (v1.1 May 2009). A report prepared by the SEDENTEXCT project www.sedentexct.eu. (Retrieved August 2009).
5. Palomo JM, Kan CH, Palomo LB, Hans MG. Three-dimensional cone beam computerized tomography in dentistry. *Dent Today* 2006;25(11):130-35.
6. Flygare L, Öhman A. Preoperative imaging procedures for lower wisdom teeth removal. *Clin Oral Invest* 2008;12:291-302.
7. Alamri HM, Sadrameli M, Alshahood MA, Sadrameli M, Alshehri MA. Applications of CBCT in dental practice: A review of the literature. *Gen Dent* 2012;60(5):390-400.
8. Tyndall DA, Rathore S. Cone-beam CT diagnostic applications: Caries, periodontal bone assessment, and endodontic applications. *Dent Clin North Am* 2008 Oct;52(4):825-41.

9. Vandenberghe B, Jacobs R, Yang J. Diagnostic validity (or acuity) of 2D CCD versus 3D CBCT images for assessing periodontal breakdown. *Oral Surg Oral Med Oral Pathol Oral Radiol Endod* 2007 Sep;104(3):395-401.
10. Tetradis S, Anstey P, Graff-Radford S. Cone beam computed tomography in the diagnosis of dental disease. *J Calif Dent Assoc* 2010 Jan;38(1):27-32.
11. Kasaj A, Willershhausen B. Digital volume tomography for diagnostics in periodontology. *Int J Comput Dent* 2007 Apr;10(2):155-68.
12. Scarfe WC, Levin MD, Gane D, Allan G. Use of cone beam computed tomography in endodontics. *Int J Dent* 2009;2009:634567.
13. Dreiseidler T, Mischkowski RA, Neugebauer J, Ritter L, Zöllner JE. Comparison of cone beam imaging with orthopantomography and computerized tomography for assessment in presurgical implant dentistry. *Int J Oral Maxillofac Implants* 2009 Mar-Apr;24(2):216-25.
14. Garg AK. Dental implant imaging: TeraRecon's dental 3D cone beam computed tomography system. *Dent Implantol Update* 2007 Jun;18(6):41-45.
15. Hatcher DC, Dial C, Mayorga C. Cone beam CT for pre-surgical assessment of implant sites. *J Calif Dent Assoc* 2003 Nov;31(11):825-33.
16. Howerton WB Jr, Mora MA. Advancements in digital imaging: What is new and on the horizon? *J Am Dent Assoc* 2008 Jun;139 Suppl:20S-24S.
17. Hua Y, Nackaerts O, Duyck J, Maes F, Jacobs R. Bone quality assessment based on cone beam computed tomography imaging. *Clin Oral Implants Res* 2009 Aug;20(8):767-71.
18. Almog DM, LaMar J, LaMar FR, LaMar F. Cone beam computerized tomography based dental imaging for implant planning and surgical guidance, Part I: Single implant in the mandibular molar region. *J Oral Implantol* 2006;32(2):77-81.
19. Ganz SD. CT-derived model-based surgery for immediate loading of maxillary anterior implants. *Pract Proced Aesthet Dent* 2007 Jun;19(5):311-18.
20. Tischler M. In-office cone beam computerized tomography: Technology review and clinical examples. *Dent Today* 2008 Jun;27(6):102-06.
21. Kumar V, Ludlow JB, Mol A, Cevidanes L. Comparison of conventional and cone beam CT synthesized cephalograms. *Dentomaxillofac Radiol* 2007;36:263-69.
22. Baumgaertel S, Hans MG. Buccal cortical bone thickness for mini-implant placement. *Am J Orthod Dentofacial Orthop* 2009;136(2):230-35.
23. Harrell WE. 3D Diagnosis and treatment planning in orthodontics. *Seminars in Orthodontics* 2009;15:35-41.
24. Mah JK, Huang JC, Choo H. Practical applications of cone-beam computed tomography in orthodontics. *JADA* 2010;141(suppl 3):7S-13S.
25. Boeddinghaus R, Whyte A. Current concepts in maxillofacial imaging. *Eur J Radiol* 2008;66:396-418.
26. Coti E, Campisi G. Advanced radiographic techniques for the detection of lesions in bone. *Endodontic Topics* 2004;7:52-72.

ABOUT THE AUTHORS

Neha Anil Patil

Senior Lecturer, Department of Oral Medicine and Radiology, MGM Dental College and Hospital, Navi Mumbai, Maharashtra, India

Rohit Gadda (Corresponding Author)

Senior Lecturer, Department of Oral Medicine and Radiology, MGM Dental College and Hospital, Navi Mumbai, Maharashtra, India
e-mail: rohitgadda@gmail.com

Rohini Salvi

Professor and Head, Department of Oral Medicine and Radiology, MGM Dental College and Hospital, Navi Mumbai Maharashtra, India

Diagnosis and Treatment of Halitosis: An Overview

Vineet Vaman Kini, Richard Pereira, Ashvini Padhye, Sachin Kanagotagi, Tushar Pathak, Himani Gupta

ABSTRACT

'Halitosis' or bad breath is an unpleasant problem that affects people socially and psychologically. Halitosis is caused by a mixture of breath with malodorous compounds emanating from different areas of the oral cavity, respiratory tract and upper digestive tracts.

Breath odor research captured the scientific community's attention during the last few decades. This has led to advances in analytical instruments used for identification and measurement of these malodorous compounds. The dental profession's response to the problem of halitosis has been met with hurdles in regards therapy often due to perceptible differences of the patient. This review attempts to highlight the identification, classification, diagnosis and treatment of halitosis.

Keywords: Halitosis, Organoleptic scoring, Volatile sulfur compounds, Sulfide monitoring, Instrumentation.

How to cite this article: Kini VV, Pereira R, Padhye A, Kanagotagi S, Pathak T, Gupta H. Diagnosis and Treatment of Halitosis: An Overview. *J Contemp Dent* 2012;2(3):89-95.

Source of support: Nil

Conflict of interest: None declared

IDENTIFICATION OF HALITOSIS

Identification of halitosis or 'bad breath' is in itself a problem due to subjectivity of perception of the examiner and the patient.¹ People often are unaware of their own bad breath.^{1,2} Our inability to smell our own oral malodor has been attributed to adaptation or dulling of sensation resulting from continual exposure. This lack of objectivity poses a hurdle not only during diagnosis but also on end results of therapy especially when a psychological angle of etiopathogenesis is identified, i.e. pseudohalitosis and halitophobia.^{3,4} Pseudohalitosis is where the oral malodor does not exist, but the patient believes that he/she has it. If after successful treatment for either genuine halitosis or pseudohalitosis the patient still believes that he/she has halitosis then the diagnosis is termed halitophobia.^{3,4}

Organoleptic/Hedonic Method

The human nose is best method to perceive malodor. This method identifies the malodorous compounds qualitatively and to an extent semiquantitatively through scoring (Table 1).⁴ This requires that patients do not consume any odorous foods and abstain from smoking and alcohol prior to examination by an odor judge subjected to the same precautions. It provides us with the identification of 'true

halitosis' caused by pathology be it by an intraoral or extraoral source. Caution should be maintained for airborne infections.

Questionnaire

This serves as a tool for assessing the social interactions of the patient and is expected to interrogate the subject on whether the halitosis was self-perceived or brought to attention by family and friends. This would highlight social problems created for the patient by halitosis and in addition would bring out confounding factors to diagnosis, such as pungent diets, alcohol and tobacco consumption. This would be critical in establishing the grounds for pseudohalitosis and halitophobia.⁵

ETIOPATHOGENESIS OF HALITOSIS

The malodorous compounds leading to halitosis are indicative of underlying diseases and metabolic disorders that need to be identified and taken into consideration.⁶⁻⁹ These conditions lead to true or genuine halitosis which is attributed to pathology warranting an interdisciplinary approach for successful therapy. Halitosis is due to the presence of odorous gases in the air expelled from the oral cavity. These compound were found to be gaseous in nature, i.e. volatile sulfur compounds (VSCs) namely hydrogen sulfide, methyl mercaptan, dimethyl sulfide, dimethyl disulfide, allyl mercaptan, allyl methyl sulfide, propyl mercaptan, methyl propyl sulfide, carbon disulfide, ammonia, dimethylamine and trimethylamine to name a few.¹⁰⁻¹² VSCs are mainly produced through putrefactive activities of bacteria present in saliva, the gingival crevice, the tongue surface and other areas (Flow Chart 1). The substrates are sulfur-containing amino acids, such as cysteine, cystine and methionine, which are found free in saliva, gingival crevicular fluid or produced as a result of proteolysis of protein substrates. The nature of these compounds lead to the quality of the malodor (Table 2).¹⁰⁻¹² The putrefactive changes can occur in both physiology and pathology leading to physiological halitosis and pathological halitosis respectively. Clinical examination is needed to determine whether the pathology is of intraoral or extraoral origin.

CLASSIFICATION OF HALITOSIS

Classification is not only imperative to understand etiopathogenesis but also for therapy especially when interdisciplinary referral is warranted.

Table 1: Organoleptic scoring of halitosis

Category	Description
0: Absence of odor	Odor cannot be detected
1: Questionable odor	Odor is detectable, although the examiner could not recognize it as malodor
2: Slight malodor	Odor is deemed to exceed the threshold of malodor recognition
3: Moderate malodor	Malodor is definitely detected
4: Strong malodor	Strong malodor is detected, but can be tolerated by examiner
5: Severe malodor	Overwhelming malodor is detected and cannot be tolerated by examiner (examiner instinctively averts the nose)

Table 2: VSCs odor characteristics

Name	Odor qualification
Hydrogen sulfide	Rotten eggs
Methyl mercaptan	Pungent, rotten cabbage
Dimethyl sulfide	Unpleasantly sweet
Allyl mercaptan	Garlic like
Allyl methyl sulfide	Garlic like
Carbon disulfide	Slightly pungent
Ammonia	Pleasantly sweet
Dimethylamine	Fishy, ammonical
Trimethylamine	Fishy, ammonical

extraoral causes) and highlighted the psychological parameters of halitosis as in pseudohalitosis and halitophobia.^{13,14}

EXAMINATION OF THE PATIENT FOR HALITOSIS

Intraoral Examination

It is carried out for intraoral pathologic halitosis and niches for putrefactive niches that contribute toward production of VSCs.^{7,9,15,16} Examination includes examination of the teeth for unrestored caries, endodontic infections, overhanging restorations and ill-fitting prosthesis which can lead to plaque accumulation, periodontal disease and food lodgment that provide substrate to the intraoral pathogens. The intraoral soft tissue niches include the dorsum of the tongue, gingival sulci/periodontal pockets, the tonsils and floor of the mouth.¹⁷⁻²⁰

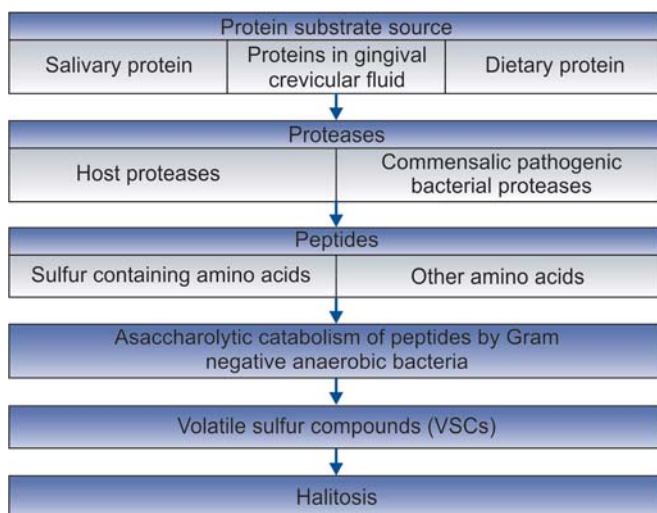
THE DORSUM OF THE TONGUE

The examination of the dorsum of the tongue should include:

- Examination for deep tongue fissures and prominent sulcus terminalis for tongue coats.
- Presence and location of the tongue coats and the thickness and color of same indicating duration and dietary influence on the same respectively.
- The presence or absence of postnasal drip residues precipitating on the posterior part of the dorsum of the tongue.
- Vigil for ulcers, erosions and pinpoint bleeding areas indicating duration and desquamative disease, *Candida*, etc.
- Presence of tonsiloliths migrating to the posterior part of the dorsum of the tongue.

Scraping the tongue with a spoon and smelling the scraping can attribute the role of the tongue coat in contributing toward halitosis. Tongue coat indices and tongue coat weight analysis can act as adjunctive tools.^{20,21,23,24}

Chairside tests, such as Halitox™ are useful as semiquantitative tests for both VSCs, such as hydrogen sulfide and methyl mercaptan, as well as polyamines like



Flow Chart 1: Production of VSCs by proteolytic bacteria causing malodor

In 1954, Attia et al classified halitosis comprising all factors contributing to the etiology of halitosis and encompassing multiple disciplines.^{6,13,14} It highlighted respiratory, gastrointestinal and systemic diseases also indicating the neurological and psychological aspects of breath malodor. Lu Dominic in 1982 classified true halitosis into physiological halitosis and pathological halitosis.^{13,14} The major drawback in this classification was that etiologies seemed to overlap in some instances particularly in reference to halitosis due to systemic causes.

Yaegaki K and Coil JM in 2000 presented a classification of halitosis (Table 3) based on the corresponding treatment needs for that existing condition with corresponding treatment needs encompassing all etiologies of halitosis including physiologic, pathologic (both intraoral and

Table 3: Classification of halitosis with corresponding treatment needs (TN)

Classification	Treatment need (TN)	Description
<ul style="list-style-type: none"> • Genuine halitosis <ul style="list-style-type: none"> – Physiologic halitosis 	TN-1	Obvious malodor, with intensity beyond socially acceptable level, is perceived. <ol style="list-style-type: none"> 1. Malodor arises through putrefactive process within the oral cavity. Neither specific disease nor pathologic condition that could cause halitosis is found. 2. Origin is mainly the dorsoposterior region of the tongue. 3. Temporary halitosis due to dietary factors (e.g. garlic) should be excluded.
<ul style="list-style-type: none"> – Pathologic halitosis <ul style="list-style-type: none"> - Oral 	TN-1 and TN-2	<ol style="list-style-type: none"> 1. Halitosis caused by disease, pathologic condition or malfunction of oral tissues. 2. Halitosis derived from tongue coating, modified by pathologic condition (e.g. periodontal disease, xerostomia) is included in this subdivision.
<ul style="list-style-type: none"> - Extraoral 	TN-1 and TN-3	<ol style="list-style-type: none"> 1. Malodor originates from nasal, pernasal and/or laryngeal regions. 2. Malodor originates from pulmonary tract or upper digestive tract. 3. Malodor originates from disorders anywhere in the body, whereby the odor is blood borne and emitted via the lungs (e.g. diabetes, hepatic cirrhosis, uremia, internal bleeding).
<ul style="list-style-type: none"> • Pseudohalitosis 	TN-1 and TN-4	<ol style="list-style-type: none"> 1. Obvious malodor is not perceived by others although the patient stubbornly complains of its existence. 2. Condition is improved by counseling (using literature support, education and explanation of examination results) and simple oral hygiene measures.
<ul style="list-style-type: none"> • Halitophobia 	TN-1 and TN-5	<ol style="list-style-type: none"> 1. After treatment for genuine halitosis or pseudohalitosis, the patient persists in believing that he/she has halitosis. 2. No physical or social evidence exists to suggest that halitosis is present.
<i>Category</i>	<i>Description</i>	
<ul style="list-style-type: none"> • TN-1 • TN-2 • TN-3 • TN-4 • TN-5 	Explanation of halitosis and instructions for oral hygiene (support and reinforcement). Oral prophylaxis, professional cleaning and treatment for oral diseases especially periodontal diseases. Referral to a physician or medical specialist. Explanation of examination data, further professional instructions, education and reassurance. Referral to a clinical psychologist, psychiatrist or other psychological specialist.	

putrescine and cadaverine based on its color changes when exposed to a sample of tongue scraping. The intensity of hue change from colorless to yellow to yellowish brown depicts loosely both the number of VSC-producing bacteria and the intensity of VSC produced which can be correlated with the quantity of tongue coat clinically present to draw clinical inferences.²²⁻²⁴

GINGIVAL SULCUS/PERIODONTAL POCKET EXAMINATION

Evidence shows that apart from the dorsum of the tongue, the gingival sulcus/pseudopocket and the periodontal pocket is the next econiche which is capable of harboring VSC-producing proteolytic anaerobic bacteria. In fact it was proposed that the periodontal pathogens through transechonical migration used to colonize the dorsum of the tongue contributing equivocally to halitosis.

The proteolytic periodontal pathogens involved in this process are *Treponema denticola*, *Porphyromonas gingivalis* and *Tannerella forsythia* which give a positive enzymatic benzoyl-DL-arginine-2-naphthylamide (BANA) test due to their trypsin like proteases, gingipains.^{24,25}

The VSCs produced by these periodontal pathogens within the periodontal pocket/gingival sulcus can be

measured by a specially designed periodontal probe, the Perio 2000 Diamond probe system.

OTHER INTRAORAL ECONICHES

Other intraoral econiches that can be involved in putrefactive proteolytic processes include the lining mucosa, floor of the mouth and hard palate mucosa and their putrefactive products are accumulated in the saliva. The saliva collected from the mouth can be collected and tested for tissue breakdown products by TOPAS™—toxicity prescreening assay for hydrogen sulfide and methyl mercaptan along with polyamines, such as putrescine and cadaverine, cystiene tolerance test for cysteine breakdown products in saliva using the salivary supernatant sediment test (SSS system) and The Swinnex filter test to determine the malodorous potential of stagnated saliva as in the stagnant saliva during nocturnal conditions contributing toward morning breath.²²⁻²⁵

EXTRAORAL EXAMINATION

Interdisciplinary referrals to physicians are warranted in the case of extraoral pathologic halitosis. The examinations would include complete systemic examination and examination of organ systems specific to the problems of

malodor.²⁶ These may include certain procedures, such as laryngoscopy, gastrointestinal endoscopy, routine radiographic procedure and laboratory diagnostic procedures to detecting systemic condition, which may have an influence on halitosis, i.e. blood borne halitosis. Their opinion on the various systemic conditions influence on halitosis is indispensable while treating the patient as a whole and should be given priority, if warranted to direct the patient to a more medically oriented treatment plan rather than just a dentally oriented treatment plan. Moreover, their evaluation may lead to more insight on psychiatric profile of the patient and may make the road to referral to a psychiatric specialist in cases of pseudohalitosis and halitophobia.²⁷

Extraoral causes of halitosis include:

Respiratory tract lesions like sinusitis, foreign bodies, atrophic rhinitis (ozena), Wegener's granulomatosis, tuberculosis, rhinoscleroma, adenoiditis, nasopharyngeal abscess, carcinoma of the larynx, laryngoscleroma, pulmonary abscess, carcinoma of the lung, bronchiectasis, necrotizing pneumonitis and empyema may all be associated with halitosis.^{6,26,27}

Gastrointestinal conditions like salivary gland dysfunction, retropharyngeal abscess, Zenker's diverticulum, congenital bronchoesophageal fistula, gastric carcinoma, hiatus hernia and pyloric stenosis, as well as with enteric infections can cause halitosis. However, the current view is that halitosis, if present in conjunction with these disorders, is actually caused by disorders of the oral cavity. The unpleasant odor emitted from the lower gastrointestinal tract is only detectable during retching or vomiting, because the esophagus is normally collapsed.^{6,26,27}

Patients with neurological conditions that cause a disordered sense of smell (dysosmia) may believe that they have halitosis; this is referred to as subjective halitosis because other people cannot detect an odor.^{6,26,27}

Subjective halitosis, i.e. halitophobia and pseudohalitosis may occur as a manifestation of a mental disorder, usually a psychosis.^{27,28} For example, if patients complain of 'rotten breath' and say that their stomach and lungs are rotting away they most probably more often than not have a form of psychosis. Such patients may also complain of foul odors around them. An examination of mental status will confirm the diagnosis. In these cases, treatment with major tranquilizers is usually necessary. In patients with depression, halitosis is usually just one of the many somatic complaints.^{27,28}

MEASUREMENT OF HALITOSIS

1. *Organoleptic measurement*: As described before it is a subjective test scored on the basis of the examiner's

perception of a subject's oral malodor. However it is not quantitative.²⁹

2. *Gas chromatography*: Gas chromatography (GC) is considered the gold standard for measuring oral malodor since it is specific for VSCs, the main cause of oral malodor. The GC equipment is expensive, bulky and the procedure requires a skillful operator. Therefore, this technology has been confined to research and not to clinical use.^{3,30}
3. *Sulfide monitoring*: Sulfide monitors analyze for total sulfur content of the subject's mouth air. Although compact sulfide monitors are inexpensive, portable and easy to use, most of them are not able to distinguish among the VSCs. For example, the Halimeter™ (Interscan Co., Chatsworth, CA) has high sensitivity for hydrogen sulfide but low sensitivity for methyl mercaptan, which is a significant contributor to halitosis caused by periodontal disease.^{31,32}
4. *Ammonia detector*: For measuring malodorous substances not having sulfide like (indole, skatole, putrescine and cadaverine which are ammoniferous compounds and cause halitosis).³¹⁻³³

The most reliable and practical procedure for evaluating a patient's level of oral malodor is still done through an organoleptic assessment by a trained clinician. Nevertheless, the use of a portable sulfide monitor is of interest, since we can quantify the changes and the patients are able to monitor their evolution through therapy. This is an important factor especially in those patients with pseudohalitosis or halitophobia.^{27,28}

TREATMENT OF HALITOSIS

Physiologic Halitosis

Practical treatment of physiologic halitosis requires TN-1. Since tongue coating is comprised of desquamated epithelial cells, blood cells and bacteria; cleaning the tongue reduces VSCs. Although brushing and flossing are not very effective in reducing oral malodor, these procedures are required to maintain good oral hygiene, and to prevent periodontal conditions, which are the most frequent causes of oral pathologic halitosis. Some kinds of mouthwashes and toothpastes are also effective in reducing oral malodor (Table 4).³⁴⁻³⁷ However, practitioners must refer to articles published in peer reviewed journals to determine whether a product is effective in reducing oral malodor. When evaluating the literature it should be noted that *in vitro* study of products is impractical for examining their ability to reduce oral malodor; the effects must be investigated *in vivo* as well. Organoleptic measurement of oral malodor is frequently employed to determine the clinical efficacy of

Table 4: Effectiveness of rinses used for the reduction of oral malodor

Method	Effectiveness in reduction of oral malodor
Rinsing with water	Effective for 15 minutes.
Use of sanguinarine rinses	No detectable decreases have been reported.
Essential phenolic oils	Low substantivity and only transient antibacterial effects, but measurable reduction.
Zinc chloride rinses	Marked reduction of VSC levels overtime. Ionic zinc inhibits VSCs for 10 hours, reduces odor by 71%.
Two-phase mouthwash	Oil, water and cetylpyridinium chloride, found very effective at full strength.
Chlorhexidine	Substantive antimicrobial agent, effective against both Gram negative and Gram positive bacterial species some unfortunate side effects, such as staining and bitter taste.
Chloride dioxide	No research to show efficacy or long-term effects. Some caution from a report by the Canadian cancer research with respect to chlorine dioxide in the water supply.
Cetylpyridinium chloride	Shown to reduce VSC production for 3 hours.

the products, but the measurement is neither objective nor scientific.³⁴

Reliable clinical research articles are available only on mouthwashes containing zinc, chlorhexidine, highly concentrated alcohol and hydrogen peroxide, demonstrating their efficacy in reducing malodor. Dental prophylaxis is one of the most important of TN-1 measure, not only halitosis patients but also dental patients must be instructed to have regular examination and scaling.^{34,35}

ORAL PATHOLOGIC HALITOSIS

As the presence of periodontal conditions is a main contributor to oral pathologic halitosis, periodontal treatment is frequently required. Hence, regular dental treatments such as restorations, root-canal treatment or extractions are required for these cases. A chronic ulcer in the oral cavity, such as a cancer, is a very rare cause of halitosis. Since a large reduction of salivary secretion causes oral pathologic halitosis, the treatment of xerostomia may reduce oral malodor. It was found that residual saliva on the posterior palate is specifically reduced in hyposalivators. So-called 'jungle breath' or 'jungle mouth' is considered to be caused by reduced salivation during sleeping. Specific treatment of this etiology with sialagogues has also been indicated for the rectification of oral malodor.^{6,34,35}

EXTRAORAL PATHOLOGIC HALITOSIS

Extraoral pathologic halitosis treatments are outside the realm of dental practitioners. If practitioners diagnose or suspect this condition, they should quickly refer a patient to a medical practitioner (TN-3).^{6,27,28}

MANAGEMENT OF PSEUDOHALITOSIS AND HALITOPHOBIC PATIENTS

Pseudohalitosis and halitophobia patients believe they have halitosis, even though offensive oral malodor is absent. A typical symptom of these conditions is that they interpret other people's behavior, such as 'covering the nose',

'averting the face' or 'stepping back' as an indication that they have oral malodor. Pseudohalitosis patients can accept the practitioner's diagnosis that oral malodor does not exist after having undergone treatment and being reinforced scientific literature support, education and explanation of examination results (TN-4).^{6,27,28}

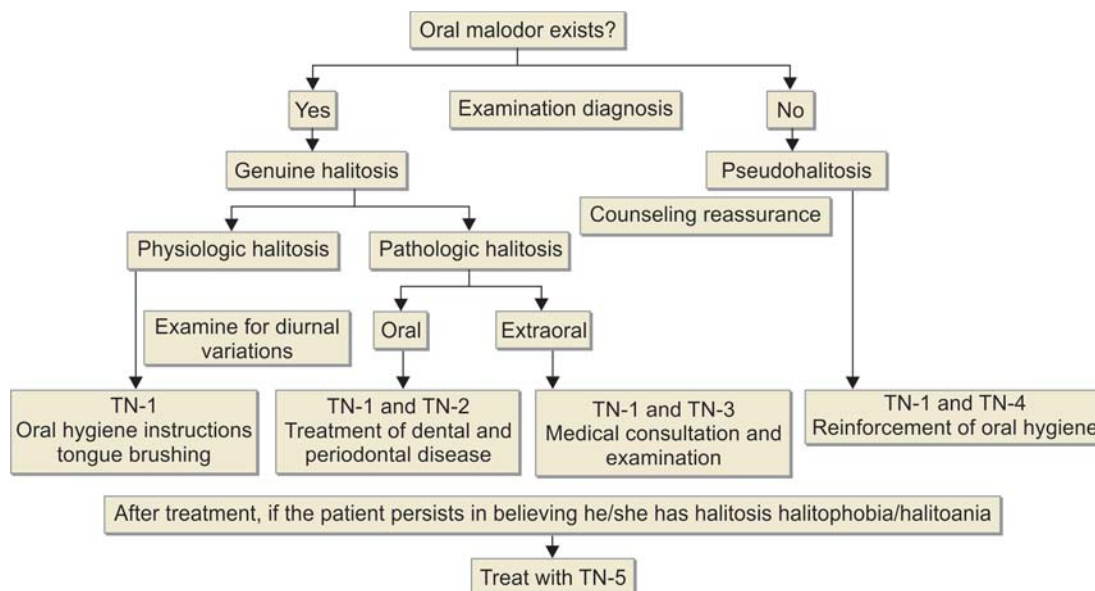
The principle of the management protocol is as follows:

- The practitioner must display attitudes of acceptance, sympathy, support and assurance toward the patient to establish rapport between him/her and the patient.
- The practitioner should not argue with the patient as to whether their oral malodor exists or not.
- The practitioner must explain that other individual's avoidance behavior is not caused by oral malodor.
- The patient must be instructed in TN-1.
- The patient must be instructed that he/she must avoid judging his/her oral malodor by other people's attitude.

Halitophobic patients are quite unhappy with their dental practitioners, who diagnose no oral malodor. Sometimes practitioners may lose their rapport with these patients. If practitioner tries to convince a patient to visit a psychological specialist (TN-5) on account of halitophobia, many patients will refuse the referral because they have no doubt that they have severe oral malodor. They still judge their oral malodor by other individuals' attitudes. Therefore, we counsel that a patient needs psychological assistance to avoid judging his/her breath by other people's gestures rather than the issue of malodor itself. If they cannot accept the referral to a specialist, some patients might develop a personality disorder, which is totally outside the realm of dental treatment.^{6,27,28}

SUMMARY AND CONCLUSION

With the ingress of technology and molecular sciences it was proved beyond doubt that oral malodor had its roots both in the oral cavity as well as other communicating spaces (GIT, upper and lower respiratory tracts and through blood circulation). This warranted a new classification of oral malodor comprising of both intraoral as well as extraoral



Flow Chart 2: Treatment protocol for halitosis

etiologies and emphasis on treatment needs based on contingency management of the disease (Ken Yaegaki, JM Coil et al) which was not reflected on previously.

In addition to organoleptic assessment of the oral malodor, the invention of sophisticated instruments, i.e. gas chromatographs, portable sulfide monitors and ammonia detectors; science has enabled us to realize the measurement of oral malodor as a reality.

The entry of chairside enzymatic tests and assays have been a very encouraging boost in the direction of recognizing oral malodor with a causative putative pathogen.

Although the current treatment modalities have rendered the clinician to cope with the problem of oral malodor, the success of therapy is subject to patient perception. Therefore, the psychological aspect of the disease should be considered to ensure effective therapy (Flow Chart 2).

REFERENCES

1. Boxy A. Oral malodor: Philosophical and practical aspects. *J Can Dent Assoc* 1997;63:196-201.
2. Idua E, Bhat R. Self-perception of breath odor. *J Am Dent Assoc* 2001;132:621-26.
3. Rosenberg M. Clinical assessment of bad breath: Current concepts. *J Am Dent Assoc* 1996;127:475-82.
4. Rosenberg M, McCullochi C. Measurement of oral malodor: Current methods and future prospects. *J Periodontol* 1992;63:776-82.
5. Yaegaki K. Clinical application of a questionnaire for diagnosis and treatment of halitosis. *Quintessence Int* 1999;30:302-06.
6. Attia EL, Marshall KG. Halitosis. *Can Med Assoc J* 1982;126:128-35.
7. De Boever EH, Loesche WS. Assessing contribution of anaerobic microflora of the tongue to oral malodor. *J Am Dent Assoc* 1995;126:1384-93.
8. Kleinberg DM, Westbay G. Salivary and metabolic factors involved in oral malodor formation. *J Periodontol* 1992;63:768-75.
9. McDowell JD, Kassebarn DK. Diagnosis and treating halitosis. *J Am Dent Assoc* 1993;124:55-64.
10. Goldberg S, Kozlavsky A, Gordon D. Cadaverine as a putative component of oral malodor. *J Dent Res* 1994;73:1168-72.
11. Kozlovsky D, Gordon. Correlation between the BANA test and oral malodor parameters. *J Dent Res* 1994;73:1036-42.
12. Gonerman A. Halitosis in medicine: A review. *Int Dent J* 2002;52:201-06.
13. Yaegaki K, Coil JM. Examination, classification and treatment of halitosis, clinical perspective. *J Can Dent Assoc* 2000;66:257-61.
14. Murata T, Yamage T. Classification and examination of halitosis. *Int Dent J* 2002;52:181-86.
15. Yaegaki K, Coil JM. Tongue brushing and mouth rinsing as basic treatment measures for halitosis. *Int Dent J* 2002;52:192-96.
16. Quiry M, Nan C, Maongardini. The effect of a 1-stage full mouth disinfection on oral malodor and microbial colonization of the tongue in periodontitis patients: A pilot study. *J Periodontol* 1998;69:374-82.
17. De Boever EH, De Vzeda M. Relationship between volatile sulphur compounds, BANA hydrolyzing bacteria and gingival health in patients with and without complaints of oral malodor. *J Am Dent Assoc* 1995;126:1393-97.
18. Morita M, Wang HL. Relationship between sulcular sulphide level and oral malodor in subjects with periodontal disease. *J Periodontol* 2001;72:79-84.
19. Morita M, Wang HL. Relationship of sulcular sulphide level to severity of periodontal disease and BANA test. *J Periodontol* 2001;72:74-78.
20. Nakano Y, Yoshimura M. Methyl mercaptan production by periodontal bacteria. *Int Dent J* 2002;52:217-20.
21. Morita M, Wang HL. Association between oral malodor and adult periodontitis: A review. *J Clin Periodontol* 2001;28:813-19.
22. Awano S, Gohara K, Kurihara E. The relationship between the presence of periodontopathogenic bacteria in saliva and halitosis. *Int Dent J* 2002;52:212-16.
23. Vaneda M, Countreasas A, Chen C. The utility of whole saliva to detectable oral presence of periodontopathic bacteria. *J Periodontol* 1998;69:828-33.

24. Louis ZG. Oral malodor: A scientific perspective. *J Can Dent Assoc* 1993;59:607-10.
25. Ratcliff PA, Johnson PW. The relationship between oral malodor, gingivitis and periodontitis: A review. *J Periodontol* 1997;70:485-89.
26. Kleinberg DM, Codipilly. Cysteine challenge testing: A powerful tool for examining oral malodor processes and treatments in vivo. *Int Dent J* 2002;52:221-28.
27. Preti G, Clark L, Cowart BJ. Nonoral etiologies of oral malodor and altered chemosensation. *J Periodontol* 1992;63:791-96.
28. Yaegaki K, Coil JM. Clinical dilemmas posed by patients with psychosomatic halitosis. *Quintessence Int* 1999;30:328-33.
29. Rosenberg M, Gelernter I, Barki M. Measurement of halitosis: Current methods and future prospects. *J Periodontol* 1992;63:776-82.
30. Furue J, Majms G, Lenton. Comparison of volatile sulphur compound concentrations measured with a sulphide detector vs gas chromatography. *J Dent Res* 2002;819:140-43.
31. Oho T, Yashida Y. Characteristics of patients complaining of halitosis and gas chromatography for diagnosing halitosis. *Oral Surg Oral Med Oral Pathol Oral Radiol Endo* 2001;91:531-34.
32. Rosenberg M, Kulkarni B. A reproducibility and sensitivity of oral malodor measurement, with portable sulphide monitor. *J Dent Res* 1991;11:1436-40.
33. Rosenberg M, Septon I, Eli I, et al. Halitosis measurement by an industrial sulphide monitor. *J Periodontol* 1991;62:487-89.
34. Coil JM and Yaegaki K. Treatment needs (TN) and practical remedies for halitosis. *Int Dent J* 2002;52:187-91.
35. Rolla G, Ski GJ. The significance of the source of zinc and its anti VSC effect. *Int Dent J* 2002;52:233-35.
36. Rosenberg M, Geleruter I, Barki M. Day long reduction of oral malodor by a two phase oil: Water mouthrinse, as compared to chlorhexidine and placebo rinses. *J Periodontol* 1992;63:39-43.
37. Loesche WJ. The effects of antimicrobial mouthrinses on oral malodor and their status relative to US Food and Drug Administration regulations. *Quintessence Int* 1999;30:311-18.

ABOUT THE AUTHORS

Vineet Vaman Kini (Corresponding Author)

Reader, Department of Periodontics, MGM Dental College and Hospital Navi Mumbai, Maharashtra, India, e-mail: drvinkin@gmail.com

Richard Pereira

Professor, Department of Periodontics, MGM Dental College and Hospital, Navi Mumbai, Maharashtra, India

Ashvini Padhye

Professor and Head, Department of Periodontics, MGM Dental College and Hospital, Navi Mumbai, Maharashtra, India

Sachin Kanagotagi

Senior Lecturer, Department of Periodontics, MGM Dental College and Hospital, Navi Mumbai, Maharashtra, India

Tushar Pathak

Senior Lecturer, Department of Periodontics, MGM Dental College and Hospital, Navi Mumbai, Maharashtra, India

Himani Gupta

Senior Lecturer, Department of Periodontics, MGM Dental College and Hospital, Navi Mumbai, Maharashtra, India

Etiological Factors of Recurrent Aphthous Stomatitis: A Common Perplexity

Niharika Swain, Jigna Pathak, Leela S Poonja, Yogita Penkar

ABSTRACT

Recurrent aphthous stomatitis (RAS) is one of the most common oral mucosal disorders. Nevertheless, while the clinical characteristics of RAS are well-defined, the precise etiology and pathogenesis of RAS remain unclear. The present article provides a detailed review of the current knowledge of various etiological factors of RAS.

Keywords: Mouth ulcers, Recurrent aphthous stomatitis, Etiology.

How to cite this article: Swain N, Pathak J, Poonja LS, Penkar Y. Etiological Factors of Recurrent Aphthous Stomatitis: A Common Perplexity. *J Contemp Dent* 2012;2(3):96-100.

Source of support: Nil

Conflict of interest: None declared

INTRODUCTION

Recurrent aphthous stomatitis (RAS; Aphthae; Canker sores), a common oral mucosal disorder that is characterized by multiple, recurrent, small, round or ovoid ulcers with circumscribed margins, erythematous haloes, and yellow or gray floors that present first in childhood or adolescence. Although it is one of the most common recurrent oral ulcerative conditions of adults and children recognized throughout the world, RAS is also one of the least understood oral diseases and is among the most vexing problems faced by affected patients and clinicians alike.^{1,2} The triggering factors that precipitate recurrent episodes in RAS patients seem to be as diverse and unique as the affected individuals themselves, which has posed a challenge for researchers in their attempts to identify a specific causation for this disease. Although the exact etiology of RAS remains obscure, there is growing lucidity with regard to its pathogenesis which has significantly influenced contemporary approaches toward its management. This article reviews the clinical features and various etiological factors of RAS.

CLINICAL FEATURES

'Aphthous' comes from the Greek word 'aphtha', which means ulcer. Despite the redundancy, the medical literature continues to refer to these oral lesions as aphthous ulcers. 'Aphthous stomatitis' has been used interchangeably with 'aphthous ulcers' and may be a more accurate terminology. Aphthous ulcers are round or oval, with a grayish yellow,

crateriform base surrounded by an erythematous halo of inflamed mucosa. For 24 to 48 hours preceding the appearance of an ulcer, most patients have a pricking or burning sensation in the affected area. The ulcer usually occurs on the nonkeratinized oral mucosa, including the lips, the buccal mucosa, floor of the mouth, soft palate and the ventral surface of the tongue.

RAS is seen worldwide and may affect up to 25% of the population.¹⁻³ Recurrent aphthous ulceration has three different variants—minor aphthous ulcers, major aphthous ulcers and herpetiform ulcers, according to the classification described by Stanley⁴ in 1972. Minor RAU (MiRAU) is the common variety, affecting about 80% of RAU patients. It is characterized by painful round or oval shallow ulcers, regular in outline, less than 10 mm in diameter, with a gray-white pseudomembrane surrounded by a thin erythematous halo. MiRAU usually occurs on nonkeratinized mucosa such as labial mucosa, buccal mucosa and floor of the mouth. It is uncommon on the keratinized mucosa. Minor RAU is the most common form of childhood RAU. The lesions recur at varying frequencies (from every few years to almost constantly) and heal within 7 to 10 days without scarring. Major RAU (MaRAU), also known as periadenitis mucosa necrotica recurrens, occurs in approximately 10% of RAU patients. The lesions are similar in appearance to those of minor RAU, but they are larger than 10 mm in diameter, single or multiple and very painful. MaRAU has a predilection for the lips, soft palate, and fauces, but can affect any site. The ulcers of MaRAU persist for up to 6 weeks or longer and often heal with scarring. Herpetiform aphthae accounts for 7 to 10% of all RAU cases. In herpetiform RAU there are 10 to 100 ulcers at a time, ulcer size is usually 1 to 3 cm, and the ulcers form clusters that coalesce into widespread areas of ulceration lasting 7 to 10 days. These ulcers are only herpes-like in appearance; herpes simplex virus has not been cultured from them.

ETIOLOGY

To date, the precise etiology of RAS has not been disclosed, despite years of collective effort on the part of many researchers. Historically, conjecture about the origin of RAS focused on a wide spectrum of potential local and systemic factors that encompassed microbial agents, hematologic and hormonal disturbances, physical injury, emotional stress and other influences. Also confounding the search for a singular

cause is the observation that aphthous-like oral ulcers often occur in conjunction with diverse conditions of a systemic nature. Included among those conditions are cyclic neutropenia, selected anemias,⁵ inflammatory bowel diseases,⁶ Behçet's disease,^{7,8} gluten-sensitive enteropathy (celiac sprue),^{9,10} relapsing polychondritis syndromes (including the so-called 'MAGIC' syndrome, which consists of mouth and genital ulcers with inflamed cartilage),¹¹ HIV infection,¹² the purported symptom complex of recurring fevers, aphthous stomatitis, pharyngitis and lymphadenopathy (FAPA syndrome).¹³

In recent years, body of evidence has emerged to suggest a genetic and an immunologic basis for RAS. These revelations largely have eclipsed speculation that RAS is caused by an infectious microorganism or one of the other previously suspected etiologic factors. They also have led to more rational and effective contemporary approaches to the management of RAS.

Genetic Factors

Some people have a well-established familial basis for RAU. As compared to the general population, the prevalence of RAS is higher when there is a positive family history, especially when both parents are affected. There is also increased disease correlation observed in identical twins as compared to fraternal twins. In familial cases of RAS, the onset of disease is earlier and attacks tend to occur more frequently than in nonfamilial cases.¹⁴⁻¹⁶ The likelihood that RAS is a genetically grounded disease is further supported by the recognized, although not entirely consistent, identification of certain histocompatibility antigen (HLA) types (e.g. HLA B12, B51, Cw7), among some groups of aphthous patients.¹⁷

Immunologic Factors

Despite the inconsistent finding and conflicting theories, mounting scientific evidences support immune dysregulation as a key mechanism underlying the pathogenesis of RAS. It is believed that the altered immune reactivity arises perhaps in response to, or in concert with, a state of presumably heightened antigenic stimulation¹⁸ exacted on a diminished mucosal barrier. A constellation of cell-mediated immunologic phenomena seems to be a consistent factor in the disease. Serologic studies that compared RAS patients and unaffected controls revealed diminished ratios of circulating CD4⁺ helper cells to CD8⁺ suppressor cells in the former group.^{19,20} It has been proposed that in RAS some unspecified antigenic influence²¹ is at the epicenter of an antibody-dependent, T cell-mediated immune response that involves a shift in local lymphocytic subpopulations that eventuates in tissue damage.²²⁻²⁴ From the observations

of several investigators it has been hypothesized that the entire process of aphthous ulceration, from initiation through progression, is instigated by the expression on oral epithelial cells of not only normally found HLA class I antigens but also HLA class II antigens.²⁵ Presumably, this renders the cells antigenically 'foreign' and consequently they become the targets of a cell-mediated immune reaction perpetrated by lymphocytes and Langerhans cells. It has been shown that in patients with aphthous stomatitis there is a heightened lymphocytotoxic effect directed against oral epithelial cells when compared to unaffected controls.²⁴⁻²⁶

Evidence for this pathogenetic mechanism is also inferred from observations that tissue biopsies of newly erupted aphthous ulcerations demonstrate agglomeration of activated T lymphocytes at the periphery of the lesions, whereas in well-established aphthae the initially predominant CD4⁺ helper/suppressor cell population is subsumed and succeeded by cytotoxic CD8⁺ lymphocytes.^{23,24} Additional indirect support for primary immune dysregulation is reflected in the long-recognized correlation between stress and outbreaks of aphthous ulcers that is reported by many RAS patients, in contrast to the notable decrease in frequency of episodes during periods of reduced stress.²⁷ This observed association is not entirely surprising, because stress is known to affect immunologic function. It also has been observed that HIV-infected patients experience oral aphthous-like ulcerations with relatively high frequency. With advancing immune depletion, their aphthous outbreaks are often dominated by larger ulcers that run a more protracted course.^{28,29} Attempts to explore the possibility that RAS is fundamentally an antibody-driven disorder have disclosed findings that are at best inconsistent and largely unresponsive. It seems that any previously held conjecture that aphthous ulcers stem from a centrally generated humoral immune mechanism rather than from local cellular immune responses to an antigenically modified oral mucous membrane was predicated on assumptions that have since been discredited.^{17,30-32}

Microbial Factors

There is little consistent evidence to support the hypothesis that RAS represents an infectious disease. In particular, from studies to determine whether there might be a connection between previously suspect L-forms of streptococci and RAS, or the adenoviruses, herpes simplex virus (HSV), varicella-zoster virus, or cytomegalovirus and RAS, the available evidence suggests that none of these microorganisms seems to be directly culpable for RAS despite continued speculation about their possible role. One should note that an antiviral agent, acyclovir, offers no beneficial effect in preventing or attenuating episodic flares of the

condition,³³ which serves to weaken arguments in favor of a possible viral causation for RAS. From occasional anecdotal cases in which patients report an apparent consistent temporal relationship between their aphthous outbreaks and an immediately antecedent reactivated (recurrent) HSV infection, it is tempting to postulate that in a narrow subset of individuals who get RAS, the herpes virus may serve as an antigenic 'trigger' that initiates the cascade of immunologic events that result in ulceration. In a limited subset of RAS patients, it is possible that this is actually the case. Presumably, such patients would benefit from appropriate therapeutic and prophylactic antiviral therapy, coupled with treatments specifically aimed at lessening the severity and frequency of the RAS episodes by modulating their supposedly heightened immune responses to the viral 'trigger'. Such therapeutic strategies probably would be best carried out in consultation with an infectious disease specialist. It must be emphasized, however, that regarding most aphthous patients, any suggestion of a causative nexus between RAS and HSV seems to represent unsubstantiated conjecture rather than proven fact.^{34,35}

Nutritional Factors

Other issues explored in the quest to determine a cause for RAS include the possible relationship of attacks to excess or deficiency of various nutritional factors, such as serum iron, folate and vitamin B₁₂, and speculation that aphthous ulcers represent the manifestation of an allergic reaction to certain foods or other ingested or contacted substances. Apart from variably favorable responses to the avoidance of gluten products in aphthous patients with documented intestinal malabsorption disease (compared to controls³⁶ and in some aphthous stomatitis patients with normal intestinal function,³⁷ evidence that RAS primarily represents an allergic response or is etiologically linked to diminished serum iron, vitamin B₁₂ or folate levels is lacking or, at best, equivocal.^{23,27,38} For any RAS patient who exhibits physical signs and symptoms that suggest the possibility of an underlying malabsorption or nutritional deficiency state or a blood dyscrasia, it is prudent to obtain a complete blood count and assays for serum folate, vitamin B₁₂ and ferritin. Should any of these tests yield findings that suggest an underlying systemic abnormality, referral to an internist or a hematologist is indicated.

The improvement of RAU with zinc sulfate supplementation has been described in an open trial³⁹ and in a case report of aphthous ulcers with zinc deficiency and immunodeficiency,⁴⁰ but such improvement was not been confirmed in later studies.^{41,42} In a Chinese study the level of serum zinc in 75 cases of RAU was found to be at a low

level but, within the normal range, and serum copper levels were also normal.⁴³ So far no information exists on the associations between RAU and other trace elements.

Environmental Factors

Stress

Earlier studies have documented an association between RAU and a variety of psychological factors including anxiety, repressed hostility, as well as job-related and other stress factors. Conversely, other studies have failed to reveal any association between anxiety, depression, psychological life stress and recurrences of RAU. In one study, in which a relaxation/imagery treatment program was used, a significant decrease in the frequency of ulcer recurrence among all treated subjects was noted.⁴⁴ Although the majority of investigators have been unable to validate the concept that stress plays an important role in the development of RAU, the literature continues to indicate that stress may play a role in precipitating RAU.

Local Trauma

A subset of patients with RAU is predisposed to develop aphthae at sites of trauma. The reason why local trauma, such as anesthetic injections, sharp foods, tooth-brushing and dental treatment, can trigger aphthous ulceration in these patients is still unknown.⁴⁵

Tobacco

Several investigators have documented a negative association between smoking and the occurrence of RAU.⁴⁶ Such a negative association has also been documented as regards the use of smokeless tobacco (chewing tobacco and snuff), as well as in patients who are smokers.⁴⁷ Paradoxically, the majority of patients with RAU are non-smokers, and in a recent study only 9% of RAU patients were found to be active smokers, compared with 25% among the control subjects.⁴⁸

Nicotine has been reported to be beneficial in RAU and in inflammatory bowel disease, and its effects may result from influences on nerve function, although these may also exert direct anti-inflammatory effects. However, the mechanism by which cigarette smoking protects against RAU is still unknown.

Food Hypersensitivity

Some investigators have correlated the onset of ulcers to exposure to certain foods, such as cows' milk, gluten, chocolate, nuts, cheese, azo dyes, flavoring agents and preservatives. Eversole et al (1982) found no significant association between RAU and three specific food items

(tomatoes, strawberries and walnuts).⁴⁹ Some investigators have noted an increased prevalence of atopy among RAU patients, whereas Wray et al (1982) found no significant difference in the incidence of atopy in RAU patients compared with the normal population.⁵⁰

Drugs

Some drugs, such as nonsteroidal anti-inflammatory drugs (NSAIDs, e.g. propionic acid, phenylacetic acid and diclofenac) can give rise to oral ulcers similar to those of RAU, along with genital ulceration or only oral ulcers in the case of piroxicam.⁵¹ An association between beta-blockers and aphthous ulcers has also been suggested. Such ulcers usually occur as an adverse side effect and disappear with discontinued usage of the drug.^{52,53}

Recently, an increased frequency in the occurrence of RAS has been reported on using sodium lauryl sulfate (SLS)-containing toothpaste. Some reduction in ulceration has been noticed on use of SLS-free toothpaste. However, because of the widespread use of SLS-containing dentifrice, it has been proposed that this may not be a true predisposing factor of RAS.⁵⁴

CONCLUSION

While RAS remains a common oral mucosal disorder in most communities of the world, its precise etiology remains unclear. No precise trigger has ever been demonstrated, and there is no conclusive evidence for a genetic predisposition to RAS in most patients. Currently, RAS is recognized as an immunologically mediated, inflammatory oral condition rather than an infectious disease. It is reasonable to suggest that for the future, anticipated new insights into the condition's origin and pathogenesis, combined with ongoing research directed toward the development of safer, more effective immunomodulating agents, render the prospect of a cure for RAS increasingly plausible.

REFERENCES

- Jurge S, Kuffer R, Scully C, Porter SR. Number VI recurrent aphthous stomatitis. *Oral Dis* 2006;12:1-21.
- Scully C. Aphthous ulceration. *N Engl J Med* 2006;355:165-72.
- Ship II. Epidemiologic aspects of recurrent aphthous ulcerations. *Oral Surg Oral Med Oral Pathol* 1972;33:400-06.
- Stanley HR. Aphthous lesions. *Oral Surg Oral Med Oral Pathol Oral Radiol Endod* 1972;33:407-16.
- Ship JA, Chavez EM, Doerr PA, et al. Recurrent aphthous stomatitis. *Quintessence Int* 2000;31:95-112.
- Glickman RM. Inflammatory bowel disease: Ulcerative colitis and Crohn's disease. In: Fauci AS, Braunwald E, Isselbacher KJ, et al (Eds). *Harrison's principles of internal medicine* (14th ed). New York: McGraw-Hill 1998:1633-45.
- Ghate JV, Jorizzo JL. Behçet's disease and complex aphthosis. *J Am Acad Dermatol* 1999;40:1-18.
- International Study Group for Behçet's Disease. Criteria for diagnosis of Behçet's disease. *Lancet* 1990;335:1078-80.
- Magro C, Crowson AN, Mihm M. Cutaneous manifestations of nutritional deficiency states and gastrointestinal disease: Behçet's disease, inflammatory bowel diseases (Crohn's disease, ulcerative colitis, celiac disease). In: Elder D, Elenitsas R, Jaworsky C, Johnson B, (Eds). *Lever's histopathology of the skin* (8th ed). Philadelphia: Lippincott-Raven 1997:359-63.
- Rizzi R, Bruno S, Dammacco R. Behçet's disease: An immune-mediated vasculitis involving vessels of all sizes [review]. *Int J Clin Lab Res* 1997;27:225-32.
- Eisenberg E. Diagnosis and treatment of recurrent aphthous stomatitis. *Oral Maxillofacial Surg Clin N Am* 2003;15:111-22.
- Ficarra G. Oral ulcers in HIV-infected patients: An update on epidemiology and diagnosis [review]. *Oral Dis* 1997;3(Suppl 1):S183-89.
- Marshall GS, Edwards KM, Butler J, et al. Syndrome of periodic fever, pharyngitis and aphthous stomatitis. *J Pediatr* 1987;110:43-46.
- Ship JA. Inheritance of aphthous ulcers of the mouth. *J Dent Res* 1965;44:837-44.
- Miller MF, Garfunkel AA, Ram CA, et al. Inheritance patterns in recurrent aphthous ulcers: Twin and pedigree data. *Oral Surg Oral Med Oral Pathol* 1977;43:886-91.
- Miller MF, Garfunkel AA, Ram CA, et al. The inheritance of recurrent aphthous stomatitis. *Oral Surg Oral Med Oral Pathol* 1980;49:409-12.
- Neville BW, Damm DD, Allen CM, Bouquot JE. Allergies and immunologic diseases: Recurrent aphthous stomatitis. In: *Oral and maxillofacial pathology* (2nd ed). Philadelphia: WB Saunders 2002:285-90.
- Vincent SD, Lilly GE. Clinical, historic, and therapeutic features of aphthous stomatitis: Literature review and open clinical trial employing steroids. *Oral Surg Oral Med Oral Pathol* 1992;74:79-86.
- Landesberg R, Fallon M, Insel R. Alterations of T-helper/inducer and T-suppressor/inducer cells in patients with aphthous ulcers. *Oral Surg Oral Med Oral Pathol* 1990;69:205-08.
- Savage NW, Mananonda R, Seymour GJ, et al. The proportion of suppressor-inducer T-lymphocytes is reduced in recurrent aphthous stomatitis. *J Oral Pathol Med* 1988;17:293-97.
- Schroeder HE, Muller-Glauser W, Sallay K. Stereological analysis of leukocyte infiltration in oral ulcers of developing Mickulicz aphthae. *Oral Surg Oral Med Oral Pathol* 1983;56:629-40.
- Greenspan JS, Gadol N, Olson JA, et al. Antibody dependent cellular cytotoxicity in recurrent aphthous ulceration. *Clin Exp Immunol* 1981;44:603-10.
- Pedersen A, Hougen P, Kenrad B. T-lymphocyte subsets in oral mucosa of patients with recurrent aphthous ulceration. *J Oral Pathol Med* 1992;21:176-80.
- Savage NW, Seymour GJ, Kruger BJ. T-lymphocyte subset changes in recurrent aphthous stomatitis. *Oral Surg Oral Med Oral Pathol* 1985;60:175-80.
- Savage NW, Seymour GJ, Kruger BJ. Expression of class I and class II major histocompatibility complex antigens on epithelial cells in recurrent aphthous stomatitis. *J Oral Pathol Med* 1986;15:191-95.
- Rogers RS, Sams WM, Shorter RG. Lymphocytotoxicity in recurrent aphthous stomatitis. *Arch Dermatol* 1974;109:361-63.
- Woo SB, Sonis ST. Recurrent aphthous ulcers: A review of diagnosis and treatment. *J Am Dent Assoc* 1996;127:1202-13.

28. MacPhail LA, Greenspan JS. Oral ulceration in HIV infection: Investigation and pathogenesis. *Oral Dis* 1997;3(Suppl 1): S190-93.
29. Phelan JA, Eisig S, Freedman PD, et al. Major aphthous- like ulcers in patients with AIDS. *Oral Surg Oral Med Oral Pathol* 1991;71:68-72.
30. Cohen L. Etiology, pathogenesis and classification of aphthous stomatitis and Behçet's syndrome. *J Oral Pathol* 1978;7:347-52.
31. Lehner T. Immunologic aspects of recurrent oral ulcers. *Oral Surg Oral Med Oral Pathol* 1972;33:80-85.
32. Ben Aryeh H, Malberger E, Gutman D, et al. Salivary IgA and serum IgG and IgA in recurrent aphthous stomatitis. *Oral Surg Oral Med Oral Pathol* 1976;42:746-52.
33. Wormser GP, Mack L, Lenox T, et al. Lack of effect of oral acyclovir on prevention of aphthous stomatitis. *Otolaryngol Head Neck Surg* 1988;98:14-17.
34. Kameyama T, Sujaku C, Yamamoto S, et al. Shedding of herpes simplex virus type I into saliva. *J Oral Pathol* 1988;17:478-81.
35. Neville BW, Damm DD, Allen CM, Bouquot JE. Viral infections: HSV, VZV, CMV. In: *Oral and maxillofacial pathology* (2nd ed). Philadelphia: WB Saunders 2002:213-24.
36. Veloso FT, Saleiro JV. Small-bowel changes in recurrent ulceration of the mouth. *Hepatology* 1987;34:36-37.
37. Wray D. Gluten-sensitive recurrent aphthous stomatitis. *Dig Dis Sci* 1981;26:737-40.
38. Olson JA, Feinberg I, Silverman S Jr, et al. Serum vitamin B₁₂, folate and iron levels in recurrent aphthous stomatitis. *Oral Surg Oral Med Oral Pathol* 1982;54:517-20.
39. Merchant HW, Gangarosa LP, Glassman AB, Sobel RE. Zinc sulphate supplementation for the treatment of recurring oral ulcers. *South Med J* 1977;70:559-61.
40. Endre L. Recurrent aphthous ulceration with zinc deficiency and cellular immune deficiency. *Oral Surg Oral Med Oral Pathol Oral Radiol Endod* 1991;72:559-61.
41. Merchant HW, Gangarosa LP, Morse PK, Strain WH, Baisden CR. Zinc sulphate as a preventive of recurrent aphthous ulcers. *J Dent Res* 1981;60A:609.
42. Wray D. A double-blind trial of systemic zinc sulfate in recurrent aphthous stomatitis. *Oral Surg Oral Med Oral Pathol Oral Radiol Endod* 1982;53:469-72.
43. Pang JF. Relation between treatment with traditional Chinese medicine for recurrent aphthous ulcer and human zinc and copper. *Zhongguo Zhong Xi Yi Jie He Za Zhi* 1992;12:280-82.
44. Andrews VH, Hall HR. The effect of relaxation/imagery training on recurrent aphthous stomatitis: A preliminary study. *Psychosom Med* 1990;52:526-35.
45. Wray D, Graywoski EA, Notkins AL. Role of mucosal injury in initiating recurrent aphthous ulceration. *Br Med J* 1981;283:1569-70.
46. Shapiro S, Olsson DL, Chellemi SJ. The association between smoking and aphthous ulcers. *Oral Surg Oral Med Oral Pathol Oral Radiol Endod* 1970;30:624-30.
47. Grady D, Ernster VL, Stillman L, Greenspan J. Smokeless tobacco use prevents aphthous stomatitis. *Oral Surg Oral Med Oral Pathol Oral Radiol Endod* 1992;74:463-65.
48. Tuzun B, Wolf R, Tuzun Y, Serdaroglu S. Recurrent aphthous stomatitis and smoking. *Int J Dermatol* 2000;39:358-60.
49. Eversole LR, Shopper TP, Chambers DW. Effects of suspected foodstuff challenging agents in the etiology of recurrent aphthous stomatitis. *Oral Surg Oral Med Oral Pathol Oral Radiol Endod* 1982;54:33-38.
50. Wray D, Vlagopoulos TP, Siraganian RP. Food allergens and basophil histamine release in recurrent aphthous stomatitis. *Oral Surg Oral Med Oral Pathol Oral Radiol Endod* 1982;54:388-95.
51. Seigel MA, Balciunas BA. Medication can induce severe ulceration. *J Am Dent Assoc* 1991;122:75-77.
52. Natah SS, Kontinen YT, Enattah NS, Ashammakhi N, Sharkey KA, Häyrynen-Immonen B. Recurrent aphthous ulcers today: A review of the growing knowledge. *Int J Oral Maxillofac Surg* 2004;33:221-34.
53. Eisenberg E. Diagnosis and treatment of recurrent aphthous stomatitis. *Oral Maxillofac Surg Clin N Am* 2003;15:111-22.
54. Preeti L, Magesh KT, Rajkumar K, Karthik R. Recurrent aphthous stomatitis. *J Oral Maxillofac Pathol* 2011 Sep-Dec;15(3):252-56.

ABOUT THE AUTHORS

Niharika Swain (Corresponding Author)

Lecturer, Department of Oral Pathology, MGM Dental College and Hospital, Navi Mumbai, Maharashtra, India
e-mail: niharikadec30@gmail.com

Jigna Pathak

Professor, Department of Oral Pathology, MGM Dental College and Hospital, Navi Mumbai, Maharashtra, India

Leela S Poonja

Professor, Department of Oral Pathology, MGM Dental College and Hospital, Navi Mumbai, Maharashtra, India

Yogita Penkar

Lecturer, Department of Oral Pathology, MGM Dental College and Hospital, Navi Mumbai, Maharashtra, India

Immediate Overdenture

Tulika S Khanna, Sandeep Vivek Gurav, Sabita M Ram, DB Nandeeshwar

ABSTRACT

The prime focus of dentistry is on preservation of teeth and other oral structures rather than replacing what is lost. An overdenture fulfills this by preserving alveolar ridge integrity and maintaining the proprioceptive ability of the periodontium. An immediate denture replaces the lost teeth and associated structures of the maxillae and mandible at the time of extraction. This case report combines the advantages of both overdenture and immediate denture and shows its stepwise fabrication.

Keywords: Overdenture, Immediate denture, Alveolar ridge preservation.

How to cite this article: Khanna TS, Gurav SV, Ram SM, Nandeeshwar DB. Immediate Overdenture. *J Contemp Dent* 2012;2(3):101-105.

Source of support: Nil

Conflict of interest: None

INTRODUCTION

Edentulousness resulting from extraction of teeth often leads to psychological problems and social isolation of the patients. Immediate dentures are recommended to avoid the period of edentulousness and restore patient's social reforms at the earliest. They also act as scaffold to mold the residual ridge and protect it while healing takes place. Immediate denture can be planned by removing all the affected teeth or by preserving a few teeth to be used as overdenture abutments.

Less resorption of alveolar bone is seen with complete denture where few teeth are preserved under the denture.¹ The periodontium around the retained teeth maintains the proprioceptive mechanism which stimulates the underlying bone and thus prevents loss of bone.

Immediate overdenture with a few retained teeth gives the opportunity for a smooth transition from dentulousness to edentulousness.

CASE REPORT

A case report for fabrication of immediate overdenture is presented.

A 62-year-old male patient reported to the Department of Prosthodontics with the complaint of missing multiple teeth and so he desired to replace them. He gave a history of loss of teeth in the last 1 year and had pain and difficulty in chewing and desired to have dentures as soon as possible. He was apprehensive about extracting all the teeth.

Extraoral examination revealed no loss of facial height. Temporomandibular joint movements were normal. Intraoral examination revealed upper and lower partially edentulous arches with 18 natural teeth present showing severe chronic periodontitis (Fig. 1).

Three teeth (3, 13, 15) exhibited grade III mobility and 10 teeth (2, 4, 9, 12, 14, 19, 20, 29, 30, 31) showed grade II mobility. Five teeth (5, 6, 11, 22, 28) exhibited grade I mobility. Gingival recession till the middle third of roots was seen with most of the teeth. No relevant intraoral findings were observed. Radiographic examination revealed significant bone loss around all teeth. As grades II and III mobile teeth were not salvageable, it was decided to extract them. Teeth with grade I mobility (5, 6, 11, 22, 28) were to be preserved as abutments for immediate overdenture.

Treatment planned was an immediate overdenture after intentional root canal treatment of the retained teeth (5, 6, 11, 22, 28).

TREATMENT PROCEDURES

Diagnostic impressions of the maxillary and mandibular arches were made in irreversible hydrocolloid. The impressions were poured in dental stone and casts obtained. These diagnostic casts were used to fabricate special tray to get properly extended final impression. Prior to making the final impression, spacing between teeth, deep undercuts due to abrasion cavities were blocked intraorally with beading wax to facilitate easy removal of the impressions without tearing (Fig. 2).

The impressions were poured in dental stone and casts mounted on semiadjustable articulator using hand articulation (Fig. 3). As teeth present maintained the vertical and centric stops no jaw relation was required.

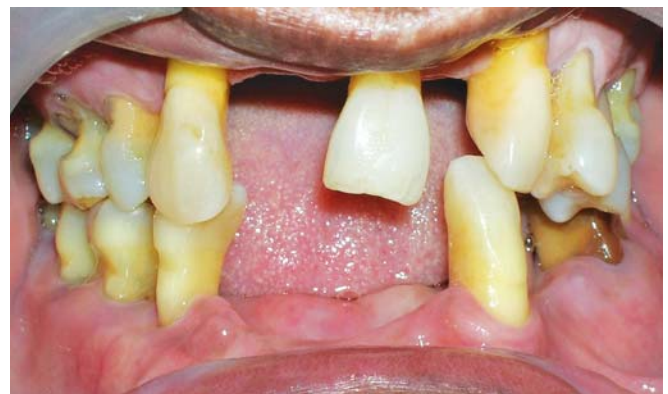

Fig. 1: Preoperative intraoral view

Posterior teeth which exhibited grades II and III mobility (2, 3, 4, 13, 14, 15, 19, 20, 29, 30, 31) were trimmed from the casts. The casts were modified so that they would closely resemble the final shape of the ridges immediately after extraction for insertion of the immediate partial denture. Modifications on the cast were done using Jerbi's guidelines in 1966.^{2,3} Posterior surgical templates were made with clear acrylic on these modified casts to help manipulate hard and soft tissues during extraction² (Fig. 4). Arrangement of the posterior teeth was done on the articulator followed by waxing and carving. These waxed up maxillary and mandibular partial dentures were processed. Finishing and polishing was done to avoid any roughness that may irritate the extraction wounds. The dentures and stent were disinfected in 5% betadine solution for 8 hours.

Posterior teeth (2, 3, 4, 13, 14, 15, 19, 20, 29, 30, 31) were extracted under local anesthesia. During extraction surgical stent was used as a reference to perform conservative alveoloplasty. The stents were tried over the extracted sites till they could be placed without tissue blanching. The dentures were now inserted intraorally (Fig. 5). Patient was instructed not to remove the denture for the first 24 hours and to swallow blood and saliva which collects in mouth. Cold packs were given to patient



Fig. 3: Final casts mounted on semiadjustable articulator

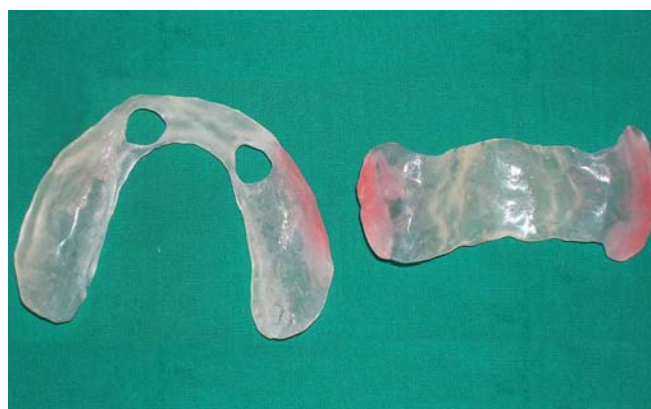

Fig. 4: Surgical templates

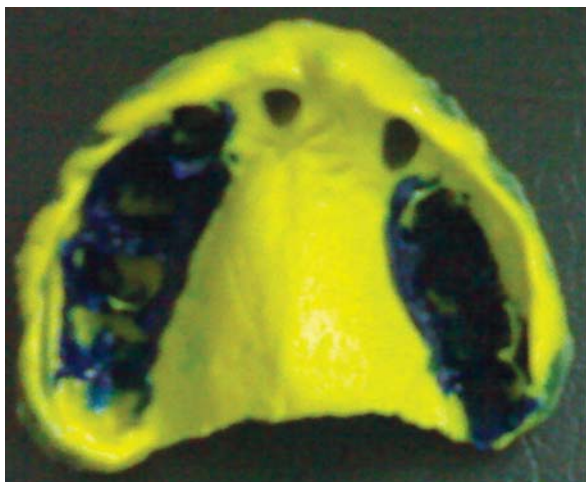
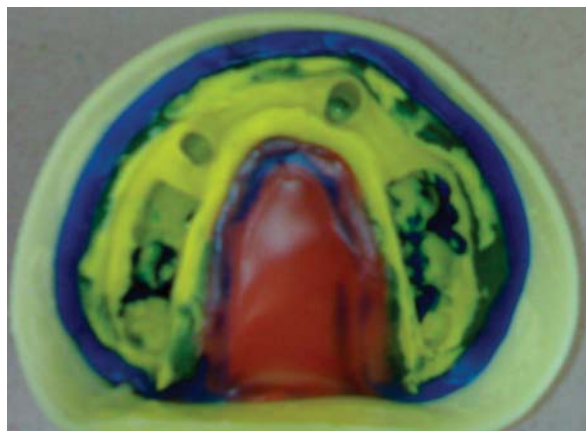


Fig. 2: Final impressions

immediately after extraction. Patient was asked to have liquid diet for that day and was recalled after 24 hours. At the recall visit the dentures were removed carefully and tissues checked for any sore spots. Occlusal adjustments were done at this visit.

During the course of healing of posterior ridges, mandibular teeth (22, 28) which were to serve as overdenture abutments, developed increased mobility and were required to be extracted. The treatment plan had to be changed at this stage. The patient would now receive an immediate overdenture for the maxillary arch and immediate denture for the mandibular arch. This was informed to the patient and consent was taken.

Intentional root canal treatment of the remaining abutment teeth (5, 6, 11) was carried out. After 3 months, posterior ridges healed well. Preliminary impression of maxillary and mandibular arches was made in alginate impression material. The impressions were poured in dental stone and casts were obtained. A partial impression tray was fabricated on these casts, this would record the edentulous distal extension region of the arch. The border molding was carried out on this tray and wash impression with zinc oxide eugenol (ZOE) was taken. The impressions were examined for completeness and placed back intraorally. This was done for both the arches. The impressions were picked up in perforated stock metal tray

which covered the anterior teeth and the posterior edentulous impression (Fig. 6). The picked up impression was poured in dental stone and master casts were retrieved. Self-cured temporary denture bases and occlusal rims were fabricated on the final cast. Jaw relation was carried out. Teeth selection was done keeping the patients' natural teeth in mind for shape, size and color. Master casts were mounted on semiadjustable articulator using face bow transfer and centric relation record.

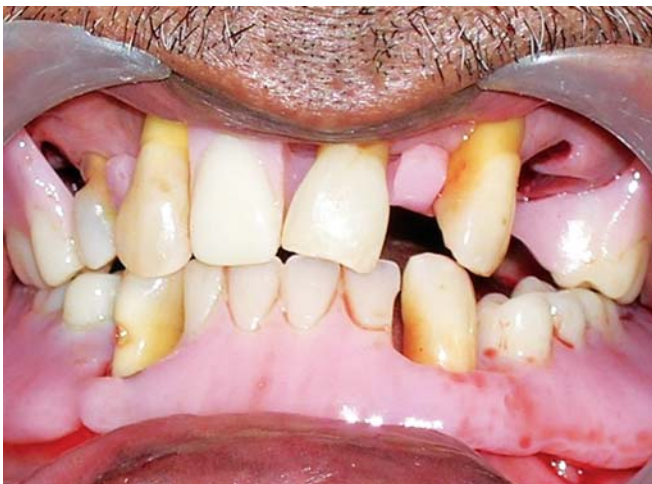
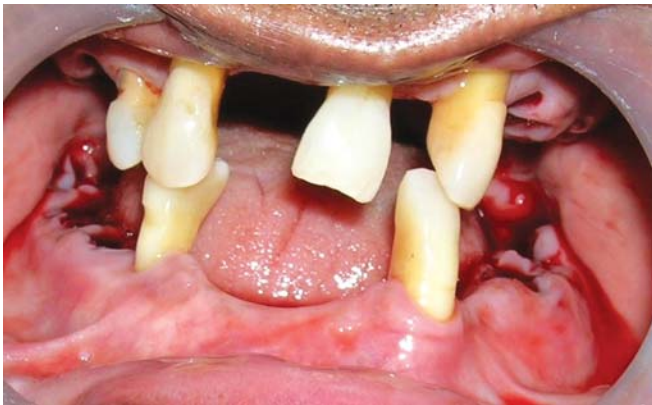
Fig. 5: Insertion of immediate partial denture

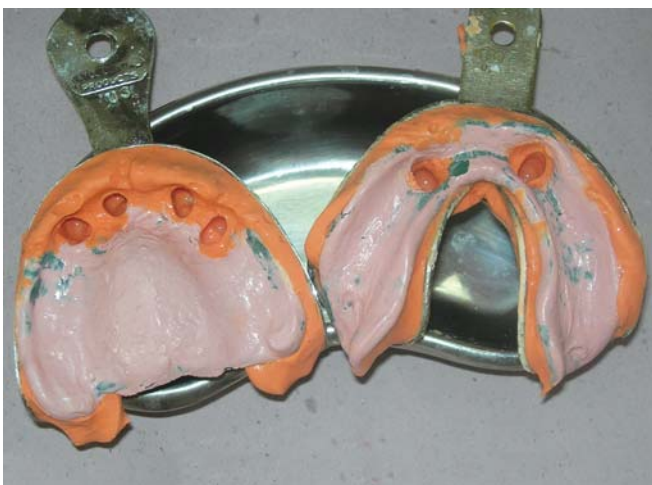


Fig. 6: Final impressions

Arrangement of posterior teeth was done on the articulator and posterior try-in carried out in patient. Anterior teeth arrangement was completed on the articulator after trimming teeth on the cast which were to go for extraction (9, 22, 28) and contouring those which were to serve as overdenture abutments (5, 6, 11). The abutment teeth (5, 6, 11) were reduced to a dome shape only 2 mm above the gingival margin (Fig. 7). After the complete teeth arrangement and wax up, processing of the dentures was done. While packing relief was placed over the prepared abutment teeth to cater for the resiliency of the soft tissue of the ridge to get better stability.

Intraoral modification of the abutment teeth (5, 6, 11) was done before the extraction in the same way as done on the cast (Fig. 8). Amalgam plugs were placed on the root canal-filled teeth. Immediately after extraction, the dentures were inserted in patient's mouth (Fig. 9). Necessary occlusal corrections were done. Patient was asked to wear the denture for the first 24 hours and was recalled the next day. Instructions regarding eating, speaking, denture cleanliness were given to patient. Patient was also explained about the possibility to reline or remake the denture later. At the recall visit fluoride application of the abutment teeth was done to minimize the risk of caries in these teeth.

DISCUSSION

Patients who are about to lose all of their natural teeth in one or both jaws may create a dilemma for themselves and their dentists. A conventional complete denture requires a significant postextraction waiting period before prosthetic impressions can be attempted on a reasonably stable residual ridge. The patient must go without teeth for several weeks leading to functional difficulty and social indignity before receiving the denture. The complete immediate denture offers a solution to this problem because it is constructed before the natural teeth are extracted and placed immediately afterward giving patient security and confidence.²

Other advantages of immediate denture being the denture acts as a bandage or splint to help control bleeding; to protect against trauma from the tongue, food or teeth if present in the opposing arch, and to promote rapid healing.^{1,4} Patients regain adequate function in speech, deglutition and mastication much sooner compared to conventional complete denture, many patients are not afraid to have teeth removed if they can have them replaced immediately. The remaining teeth aid in establishing the vertical dimension of occlusion and in positioning the artificial replacement. The disadvantages include initial high ridge resorption which often makes relining or remaking compulsory.

Retaining roots beneath dentures aids in preservation of proprioception and reduce bone resorption. By retaining

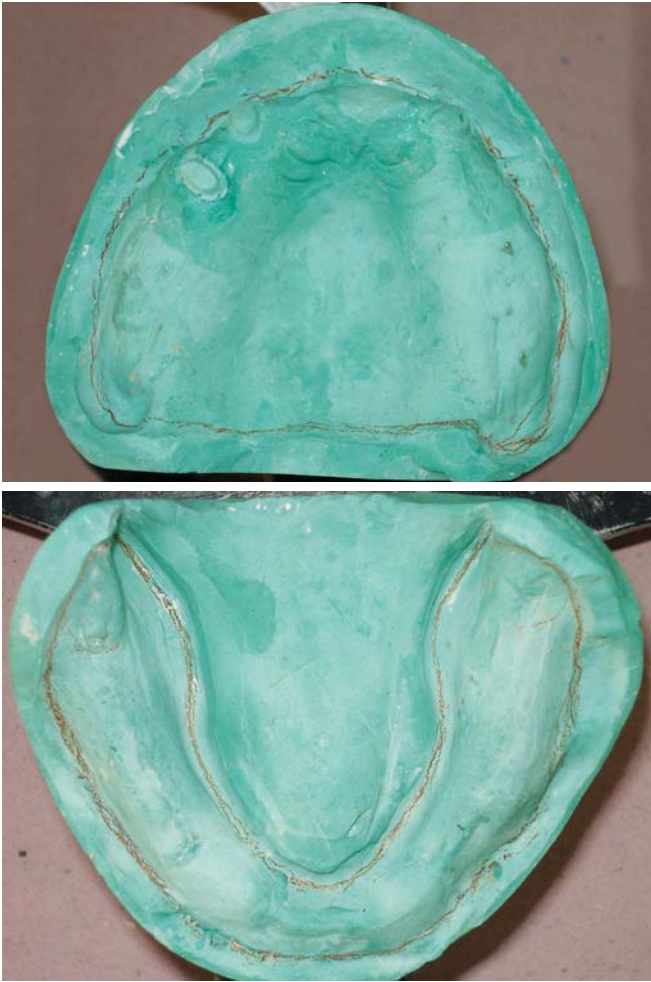


Fig. 7: Final casts

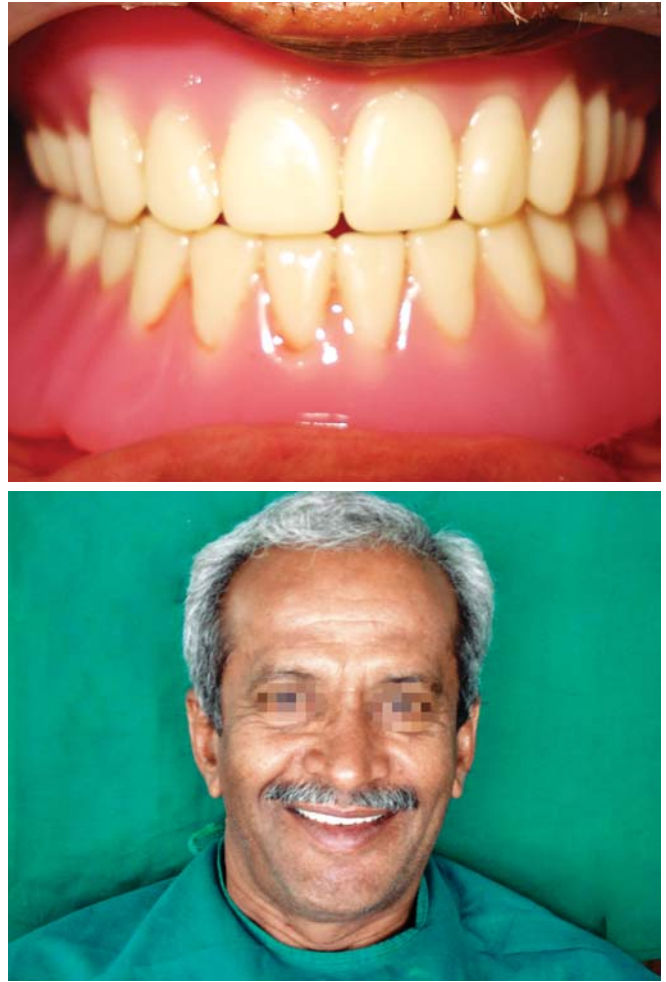


Fig. 9: Insertion of maxillary immediate overdenture and mandibular immediate denture

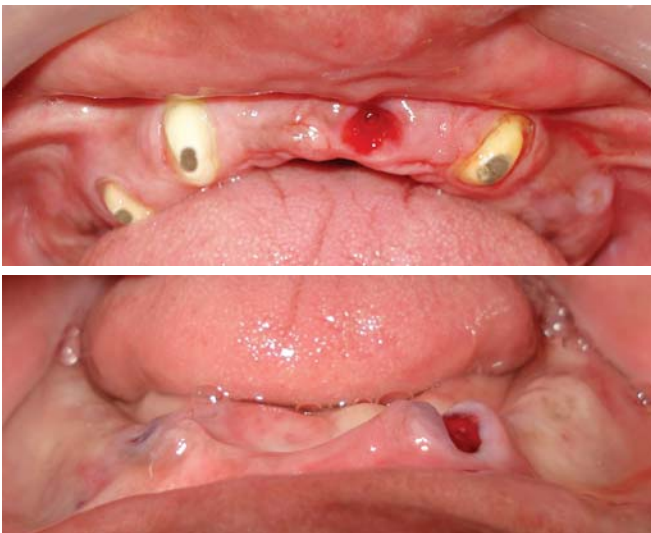

Fig. 8: Abutment teeth (5, 6, 11) prepared intraorally and anterior teeth extraction

the mandibular canines in the use of an overdenture, the resorption of the alveolar bone surrounding these teeth was shown to be reduced by eight times between the canines and it also preserved in both height and width posterior to the canines.⁴

In the present case, the selected abutment teeth were reduced so that only 2 mm crown remains above gingival margin. The reduction in crown height for overdenture has several advantages. This creates adequate space for the overlying artificial denture tooth and denture base, reduces the lateral stresses and lever action of the tooth. It also forms the basis of using periodontally compromised teeth which otherwise would have been indicated for extraction.

The retained tooth roots, used for overdenture, transfer occlusal forces to the alveolar bone through the periodontal ligament and maintain alveolar ridge morphology.^{5,6}

Pacer and Bowman found that the overdenture patient possessed more typical sensory function which is closer to natural teeth than a complete denture patient in discriminating between occlusal forces. The periodontal receptors also actively influence the cyclic joint movements of mastication by influencing the muscles of mastication by their proprioceptive feedback mechanism.⁷

The two-phase procedure was followed to ensure proper healing of posterior segment before denture placement and at the same time avoids initial rapid resorption in crucial maxillary and mandibular posterior regions.

CONCLUSION

A smooth psychological and physiological transition of patient from dentulousness to edentulousness is very important for the success of complete denture therapy. Immediate denture and overdenture treatment modality play very important role in the same. The combined advantages of immediate denture and overdenture can be gained by careful multidisciplinary approach. Thorough treatment planning and patients cooperation is important aspect of these otherwise time consuming and tedious procedures. With more emphasis on implant retained prosthesis, one should not ignore the easy and economical way of ridge preservation by overdenture way.

REFERENCES

1. Nimmo A, Winkler S. Conventional immediate denture. In: Winkler S (Ed). Essentials of complete denture prosthodontics (2nd ed). New Delhi: Ishiyaku EuroAmerica Inc AITBS Publishers 2000:361-74.
2. Stillwell KD, Amir J. A clinical pathway for complete immediate denture therapy: Successful prosthetic management for hopeless dentitions. *Gen Dent* 2008;6:380-89.
3. Jerbi FC. Trimming the cast in the construction of immediate dentures. *J Prosthet Dent* 1966;16:1047-53.
4. Crum RJ, Rooney GE Jr. Alveolar bone loss in overdenture a 5-year study. *J Prosthet Dent* 1978;40:610-13.
5. Fenton AH. The decade of overdenture 1970 to 1980. *J Prosthet Dent* 1998;79:31-36.
6. Morrow RM, Feldmann EE, Rudd KD, Trovillion HM. Tooth-supported complete denture: An approach to preventive prosthodontics. *J Prosthet Dent* 1969;21:3-22.
7. Pacer FJ, Bowman DC. Occlusal force discrimination by denture patients. *J Prosthet Dent* 1975;33:602-09.

ABOUT THE AUTHORS

Tulika S Khanna (Corresponding Author)

Reader, Department of Prosthodontics, MGM Dental College and Hospital, Navi Mumbai, Maharashtra, India, e-mail: ktuls18@gmail.com

Sandeep Vivek Gurav

Lecturer, Department of Prosthodontics, MGM Dental College and Hospital, Navi Mumbai, Maharashtra, India

Sabita M Ram

Dean, Department of Prosthodontics, MGM Dental College and Hospital, Navi Mumbai, Maharashtra, India

DB Nandeeshwar

Professor and Head, Department of Prosthodontics, Bapuji Dental College and Hospital, Dabangere, Karnataka, India

Osteochondroma of the Mandibular Condyle

Sushrut Vaidya, Sunil Sidana, Jyotsna Galinde, Srivalli Natrajan

ABSTRACT

Osteochondroma is the most common benign bone tumor but rare in the head and neck region because of intramembranous origin of craniofacial bones. In the head and neck it occurs most commonly at tip of coronoid or condylar process. Clinically features can mimic condylar hyperplasia. This case report adds to the growing knowledge about this rare tumor.

Keywords: Osteochondroma, Mandible, Condyle.

How to cite this article: Vaidya S, Sidana S, Galinde J, Natrajan S. Osteochondroma of the Mandibular Condyle. *J Contemp Dent* 2012;2(3):106-108.

Source of support: Nil

Conflict of interest: None

INTRODUCTION

Osteochondroma, also called osteocartilaginous exostosis, is the most common benign bone tumor.¹ It is characterized by a cartilage-capped osseous projection protruding from the surface of the affected bone.² Osteochondromas in the head and neck appear rarely because of the intramembranous origin of most craniofacial bones.³ This rare disease of the jaws usually occurs at the condyle or the tip of the coronoid process.⁴ Malocclusion and progressive facial asymmetry are common presenting physical signs.³ Osteochondroma of the condyle can be treated by selective tumor excision or total condylectomy with or without reconstruction.

CASE HISTORY

A 42-year-old male patient was referred for evaluation of asymmetrical enlarged mandible of 1 year duration. On examination, there was gross facial asymmetry with chin

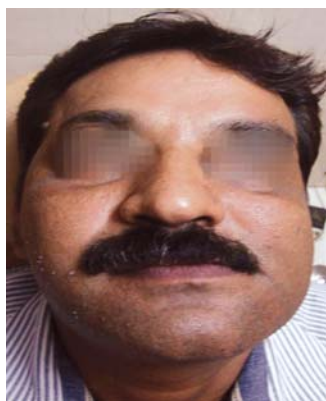

Fig. 1: Gross facial asymmetry with chin deviated to the left

deviated toward the left (Fig. 1). The midline was shifted 10 mm to the left and there was crossbite in centric relation (Fig. 2). Orthopantomogram (OPG) showed radiopacity located at the right condyle region (Fig. 3). Computed tomography (CT) scan showed a bony lesion arising from the condylar head and situated superomedially (Fig. 4). A provisional diagnosis of osteochondroma was made. The bony mass was almost twice the size of the condyle. A total condylectomy was planned.

Under nasoendotracheal intubation, a modified Al kayat and Bramley incision was taken. The incision was extended to the temporal fascia. At the root of the zygomatic arch, the superficial layer of the temporalis fascia was incised anterosuperiorly at 45° angle. The periosteum was then incised to expose the zygomatic arch. Incision was made over the capsule and condyle and bony mass was exposed (Fig. 5). The lateral pterygoid attachment was cut and

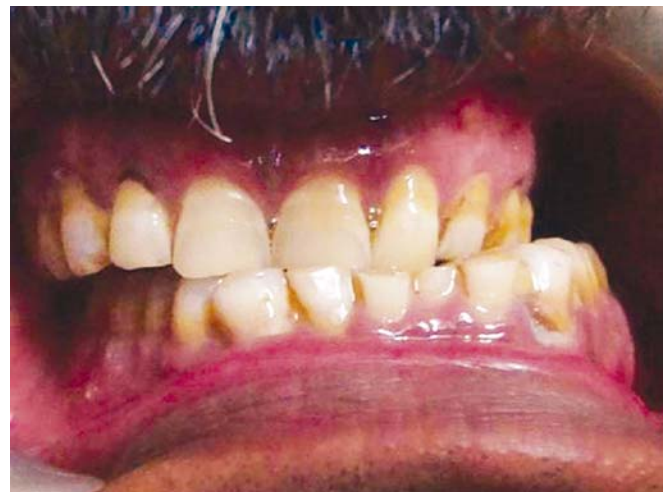

Fig. 2: Occlusion showing shift of lower midline to left with crossbite

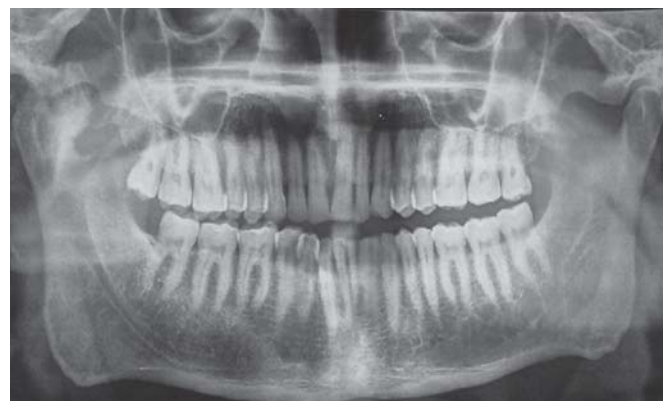

Fig. 3: OPG showing radiopacity in relation to right condyle

detached from the condyle. A bony cut was made at the level of neck of condyle, removing tumor along with part of the condyle (Fig. 6). The remaining condylar stump was smoothed. Disk was left *in situ* and the capsulorrhaphy was performed. Postoperatively, patient developed slight contralateral open bite which was corrected conservatively with intermaxillary guiding elastics. Patient was reviewed after 6 months and there was no malocclusion or asymmetry present (Figs 7 and 8). Histopathology confirmed the bony mass to be an osteochondroma (Fig. 9).

DISCUSSION

Osteochondroma can be confused with condylar hyperplasia as clinical presentation can be similar. Condylar hyperplasia is seen in a younger population and consists of a progressive generalized enlargement of the entire condyle, which arrests after the growth period. Osteochondromas are pedunculated or sessile lesions that generally grow away from the native

site of growth, usually along the muscles and tendons attached to the native bone. They continue to grow even after the patient attains skeletal maturity.⁵

The presentation varies with the size of the tumor and its main vector of growth. The usual signs of facial deformity are related to displacement of the chin point to the contralateral side from the lesion with an ipsilateral open bite. In some cases, asymmetric prognathism may occur along with bowing of the lower border of the mandible on the ipsilateral side, while compensatory down growth of the maxilla on the ipsilateral side to compensate for the open bite may give rise to a cant of the maxillary occlusal plane. These types of facial asymmetry are also seen in condylar hyperplasia and hemifacial hypertrophy, which has to be distinguished from osteochondroma.³

The treatment protocol for this disease is still controversial. Conventional approach has been to undertake total condylectomy. Intermaxillary elastics are required after condylectomy for 3 to 4 weeks to guide the patient occlusion. Due to exophytic nature of this lesion, a conservative approach has been advocated recently with excision of tumor and preservation of as much condyle as possible.^{6,7} The arguments against a conservative approach are possible inadequate removal of the tumor with recurrence of the lesion or possible malignant change. The recurrence rate of osteochondroma generally is 2% irrespective of the type of procedure and malignant change may occur in about 5% of cases with multiple hereditary lesions but is very rare in solitary lesions (<1%).^{8,9}

A costochondral graft or vertical osteotomy of ramus may be used after total condylectomy for reconstruction. In case where growth modulations have already occurred, gnathic procedures are required to correct asymmetry of the face.¹⁰

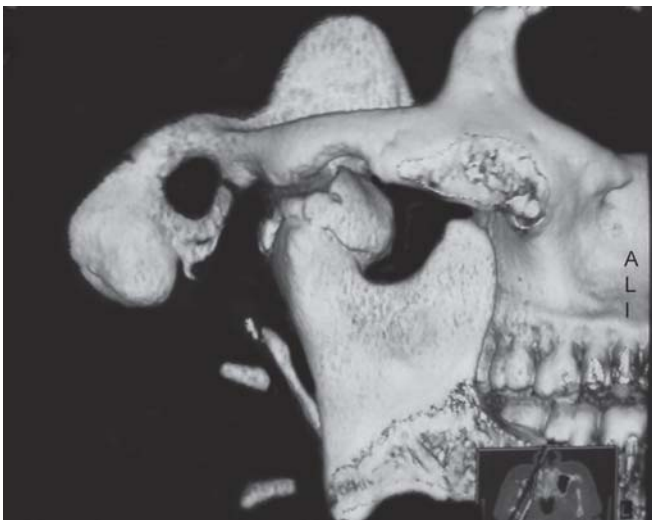


Fig. 4: Three-dimensional CT scan showing bony mass arising from condylar head and growing in a superomedial direction

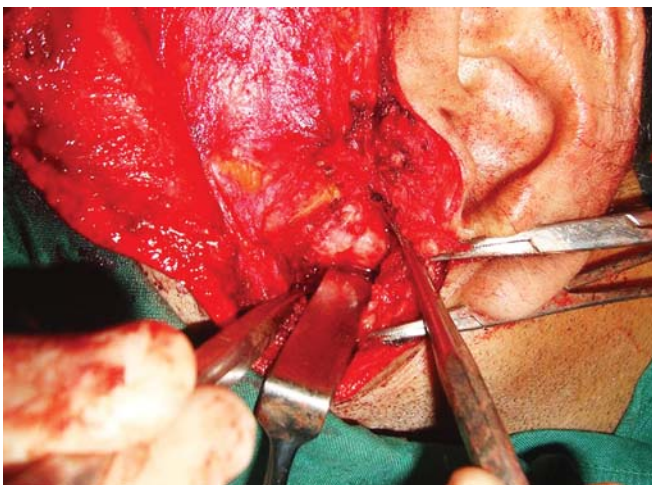


Fig. 5: The exposure of bony mass through the preauricular incision

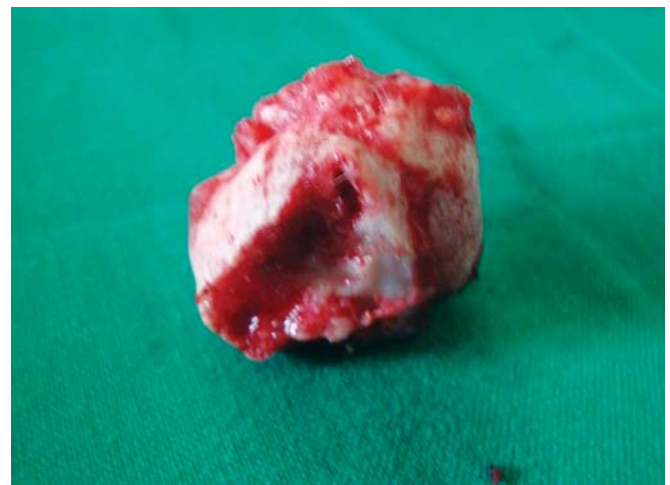

Fig. 6: The excised bony mass along with part of the condyle



Fig. 7: Postoperative photograph showing no facial asymmetry

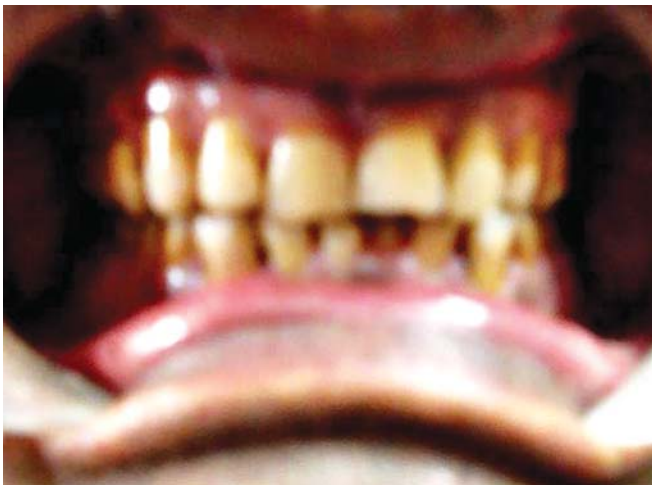

Fig. 8: Postoperative occlusion

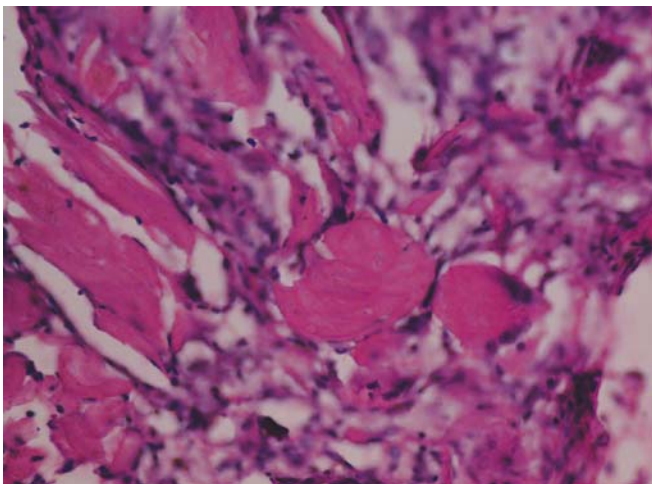


Fig. 9: Photomicrograph confirming the diagnosis of osteochondroma

REFERENCES

1. Lichtenstein L. Bone tumors (5th ed). St Louis, MO: CV Mosby 1977.
2. Ribas M, De O, Martins WD, et al. Osteochondroma of the mandibular condyle: Literature review and report of a case. *J Contemp Dent Pract* 2007;8:52.
3. Ord RA, Warburton G, Caccamese JF. Osteochondroma of the condyle: Review of 8 cases. *Int J Oral Maxillofac Surg* 2010;39: 523-28.
4. Allan JH, Scott J. Osteochondroma of the mandible. *Oral Surg* 1974;37:556.
5. Kumar VV. Large osteochondroma of the mandibular condyle treated by condylectomy using a transzygomatic approach. *Int J Oral Maxillofac Surg* 2010; 39:188-91.
6. Wolford LM, Mehra P, Franco P. Use of conservative condylectomy for treatment of osteochondroma of the mandibular condyle. *J Oral Maxillofac Surg* 2002;60:262-68.
7. Aydın MA, Küçükçelebi A, Sayilkan S, Celebiođlu S. Osteochondroma of the mandibular condyle: Report of two cases treated with conservative surgery. *J Oral Maxillofac Surg* 2001 Sep;59(9):1082-89.
8. Unni KK. Dahlin's bone tumors. General aspects and data on 11,087 cases (5th ed). Philadelphia, PA: Lippincott-Raven 1996.
9. Barrett AW, Hopper C, Speight PM. Oral presentation of secondary chondrosarcoma arising in osteochondroma of the nasal septum. *Int J Oral Maxillofac Surg* 1996;25:119-21.
10. Franco PF, Wolford LM. Conservative surgical reconstruction of the TMJ following condylectomy for osteochondroma. *J Oral Maxillofac Surg* 1997;55:107.

ABOUT THE AUTHORS

Sushrut Vaidya

Reader, Department of Oral and Maxillofacial Surgery, MGM Dental College and Hospital, Navi Mumbai, Maharashtra, India

Sunil Sidana (Corresponding Author)

Reader, Department of Oral and Maxillofacial Surgery, MGM Dental College and Hospital, Navi Mumbai, Maharashtra, India
e-mail: drsunilsidana@gmail.com

Jyotsna Galinde

Professor and Head, Department of Oral and Maxillofacial Surgery
MGM Dental College and Hospital, Navi Mumbai, Maharashtra, India

Srivalli Natrajan

Professor, Department of Oral and Maxillofacial Surgery, MGM Dental College and Hospital, Navi Mumbai, Maharashtra, India

Piezography: An Innovative Technique in Complete Denture Fabrication

Jayanta Bhattacharyya, Preeti Goel, Soumitra Ghosh, Samiran Das

ABSTRACT

Increasing life expectancy, age-related reduction in adaptability and progressive severe mandibular resorption, all add to the difficulty in achieving prosthetic success. The conventional mandibular denture is usually less retentive than the maxillary one and successful treatment involves the development of lingual retention for the mandibular denture. Several methods taking into account physiologic function with an objective to enhance denture retention and comfort during mastication have been developed since many decades. The present article describes piezography as a method to enhance retention, stability and function for the mandibular denture through a case report.

Keywords: Geriatrics, Piezography, Retention, Speech, Soft liner, Neutral zone, Stability.

How to cite this article: Bhattacharyya J, Goel P, Ghosh S, Das S. Piezography: An Innovative Technique in Complete Denture Fabrication. *J Contemp Dent* 2012;2(3):109-113.

Source of support: Nil

Conflict of interest: None declared

INTRODUCTION

In the field of oral rehabilitation, particularly in geriatric prosthodontics, several sources may contribute to the performance of complete dentures. It is our general experience that lower denture is relatively less stable than the upper one. Increasing life expectancy, age-related reduction in adaptability and progressive severe mandibular resorption further worsens the condition. The situation demands a definitive and qualitative approach to overcome these difficulties. The most common errors might be attributed to insufficient tissue coverage, improper occlusion of the prosthesis, poor vertical and maxillomandibular relationships, incorrect tooth positioning and behavioral problems. One of the philosophies that was introduced to overcome the challenge of unstable denture in clinics was the concept of neutral zone.¹ The neutral zone concept was based on neuromuscular control on the polished surface of denture and positioning the teeth in space where the oral musculature and tongue forces are nullified by each other. However, the conventional as well as functional techniques have certain demerits. Therefore, Klein in 1974 introduced a method, named piezography, which recorded the prosthodontic space for teeth placement using speech.² In the following case presentation, we tried to implement

the piezographic technique in the fabrication of complete denture in a patient with long-standing edentulousness and severely resorbed mandibular ridge.

REVIEW OF LITERATURE

Piezography in complete denture fabrication is a technique used to record shapes by means of pressure, a method of recording a patient's denture space in relation to oral function.²⁻⁴ The term piezograph was coined by Klein in 1974 from the Greek term meaning 'a shape formed by pressure'.

Regarding complete denture treatment, several methods that take physiological function into account have been developed since the 1930s. These studies have clarified that the buccolingual tooth position and the contour of the polished surface are important for denture retention and stability.^{5,6} Fahamy and Kharat reported that artificial teeth were arranged over the center of the alveolar ridges in conventional dentures, which was found to be better in mastication.⁷ However, all the participants in their study experienced a superior sense of comfort and speech ability with the neutral zone denture and selected the latter over the conventional one.

The idea behind positioning artificial teeth in the neutral zone has two objectives. First, the teeth will not interfere with normal muscle function and secondly, the forces exerted by the musculature against the dentures will be more favorable for stability and retention.⁸ Piezography helps to record the neutral zone. The denture fabricated based on piezography is more stable than the other conventional and functional techniques like swallowing.

Considering that a person swallows up to 2,400 times per day⁹ and that during the entire swallowing sequence, teeth come into contact for less than a second,¹⁰ it may be concluded that less than 40 minutes of tooth-to-tooth contact occurs per day during function. Since a person speaks much more than he involves in swallowing, we should follow phonation method more often to fabricate dentures for more stable denture prosthesis.

The buccolingual center of the occlusal table obtained by piezographic technique for fabrication of complete dentures is generally located slightly to the buccal of the residual alveolar ridge.¹¹ Morikawa et al (1983) reported that the centerline of the neutral zone was located 1.9 mm to the buccal side of the alveolar crest.¹² It is observed that

longer the period of edentulousness, the more buccally located the neutral zone was from the crest of the alveolar ridge.¹³ The piezographic techniques employ silicon-based soft liners which are quite advantageous due to suitable viscoelastic property, ample working and setting time, ability to be injected gradually over several applications and easy to handle and work over patient.¹⁴

Although this technique can be used for all patients requiring a complete denture, there are specific situations where piezography helps fabricate a more stable and retentive prosthesis. Patients with long period of edentulousness, having a severely resorbed lower ridge are most benefited by this technique. Concave foundation of lower bones, compromised earlier denture and elderly patients are also good candidates for this method. Several advantages exist with this technique. As speech is employed for recording the denture space, the patients can practice before the impression is taken. The procedure is easy to understand, especially for the elderly. It is easy to inspect for proper oral function while the patients pronounce the phonemes and allows precise placement of artificial teeth.

CASE REPORT

An elderly male patient aged 60 years, came to the Department of Prosthodontics, Guru Nanak Institute of Dental Sciences and Research, with the chief complaint of loss of all his teeth and inability to chew. On oral examination it was seen that the patient had a severely resorbed mandibular ridge, loss of vertical dimension, collapse of facial profile and loss of muscle tonicity. Lack of nutrition was evident due to inability to chew food properly. Conventional method was not considered and we decided to implement piezographic technique to manage the case.

Piezography is a technique used to record shapes by means of pressure for recording a patient's denture space in relation to oral function. It involves introduction of a moldable material into the mouth to allow unique shaping by various functional muscle forces. Speech is employed in the registration of the denture space by this technique.

The preliminary steps were performed following the standard procedures. Primary and final impressions were made for both the maxillary and mandibular ridges. Occlusal rims were fabricated. The upper rim was adjusted parallel to the Camper's line and 2 mm visibility was established.³ The vertical dimension both at occlusion and at rest was recorded. A freeway space of 2 mm was maintained. The wax rim and cast assembly were mounted on a mean value articulator. The piezographic method was carried out from this position onwards. Since the technique was based on phonetics, the patient was made to practice pronouncing certain phonemes before it was actually implemented. The

speech exercise helped mold the material that was inserted in the mouth providing the prosthodontic space. The patient was asked to say 'SIS' four times followed by a strong 'TO' in order to obtain the posterior molding. Anterior piezography was obtained by asking the patient to pronounce T, D, M, P five times in a sequence clearly and vigorously. Once satisfied about the clarity of speech, we proceeded with the next step.

Next, the mandibular rim was removed from the cast and a stabilized base plate was fabricated from self-cure acrylic resin. Grooves were made on the external surface so that the moldable material can adhere to the acrylic (Fig. 1). A silicon-based self-polymerizing soft liner was used (Ufi Gel P, Voco Dental). Prior to placement of the base plate in the mouth, silicon adhesive was applied on top of the base plate for better adhesion. The maxillary rim was placed in the mouth. Upper anterior teeth were arranged so that it improved his speech during the pronunciation of phonemes (Fig. 2). Initially, the soft liner was first placed on the right side and the patient was instructed to pronounce the phonemes (Fig. 3). Once the material set, the piezographic record was checked and the same was done for the left side (Fig. 4). After the posterior dam was obtained, moldable material was placed anteriorly and the patient was asked to say 'TDMP'. The final dam was kept on the mandibular cast and inspected (Figs 5 and 6). Excess was removed with a knife and adjusted to the required height.

Analyzing piezography, it was noted that the lateral border of the tongue had created its impression on the dam. A similar observation was recorded for the apex of the tongue, which indicated its excursion and occupied space. Piezography of the vestibular part showed the muscular action of both the masseter and the buccinator muscles, which gave information about the available space for the posterior teeth arrangement and about the anterior teeth inclination.

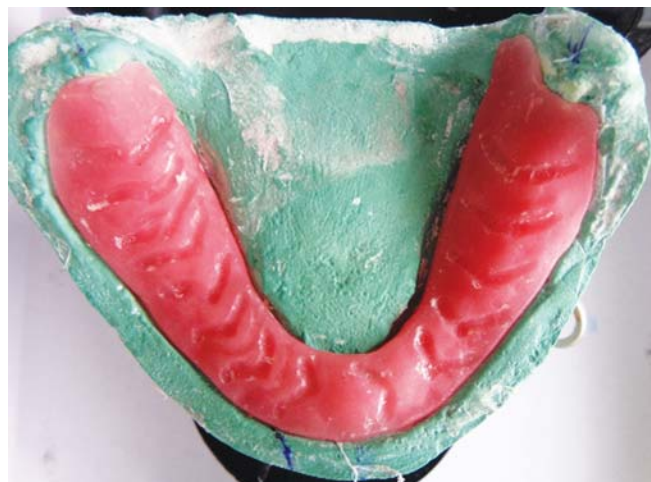

Fig. 1: Retentive grooves on acrylic for the moldable material

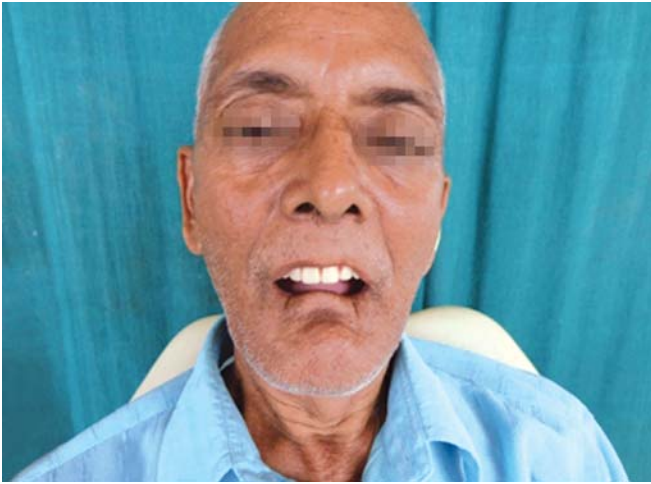

Fig. 2: Upper anterior teeth were arranged in a way that patient's phoneme pronunciation was improved

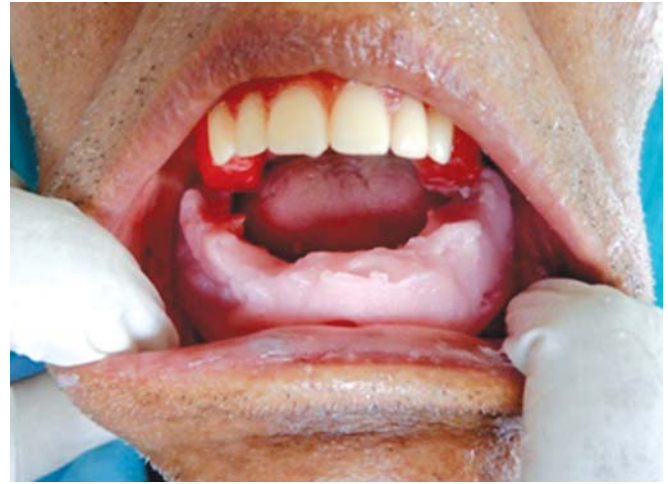

Fig. 5: Material molded anteriorly

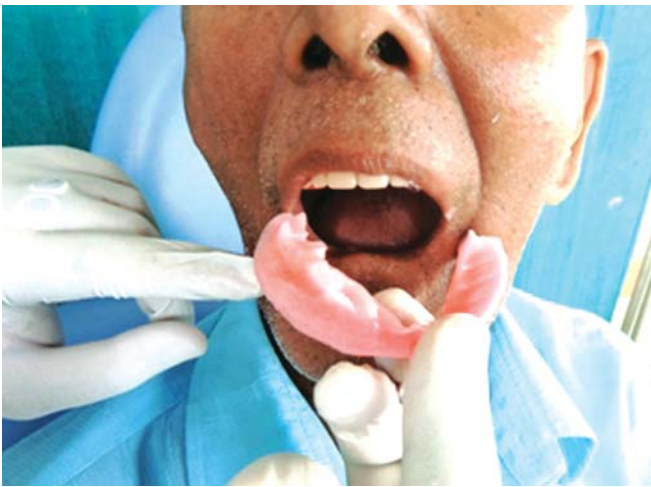

Fig. 3: Soft liner added on the right side of the plate

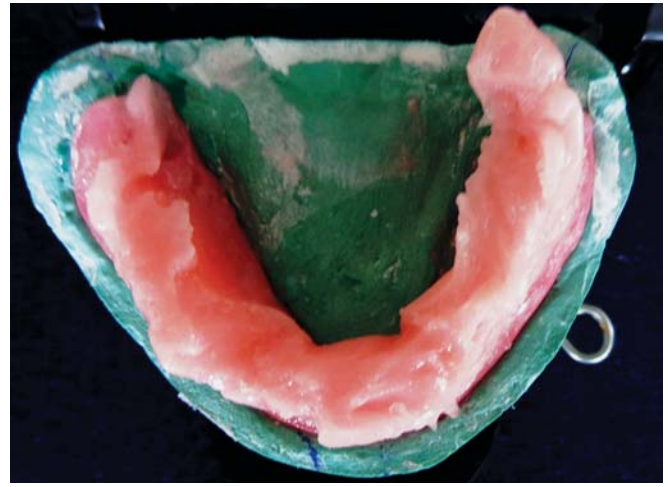


Fig. 6: Final dam kept on the mandibular cast and excess removed with a knife

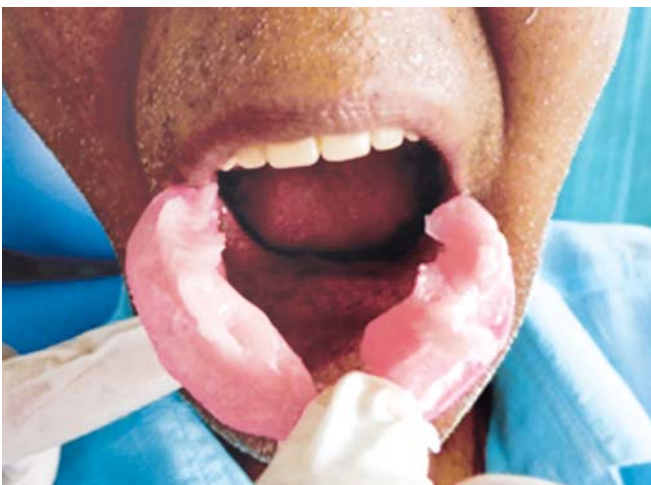

Fig. 4: Soft liner added on the left side of the plate

The exact neutral zone space was obtained with this method. The main objective being to convert this record into usable space for arranging teeth, a silicon index was fabricated over the mandibular cast. Grooves were placed

on the land area (two right and left side, one anteriorly) so that the index could be repositioned. Silicon putty material was mixed and index was made by adapting around the piezograph on outer and inner sides (Fig. 7).

After the dam was removed, the void was filled with molten wax to obtain a new wax rim (Fig. 8). The wax rim was adjusted to the predetermined vertical dimension and placed in the articulator. The posterior teeth were now arranged in the newly obtained space (Fig. 9). The waxed up teeth arrangement was tried in and esthetics and speech was adjusted and corrected. Dentures were finally fabricated and inserted after correcting processing errors (Fig. 10) Occlusion was satisfactory. Facial profile improved drastically (Fig. 11) and the denture was stable functionally.

CONCLUSION

Piezographic method for complete mandibular denture construction provides the patient with a great degree of

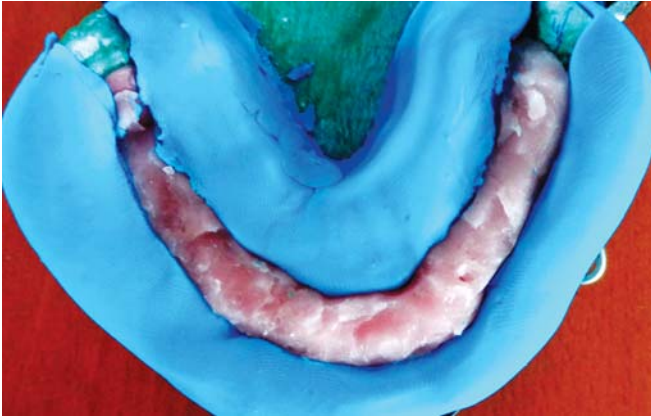


Fig. 7: Silicon putty index fabricated

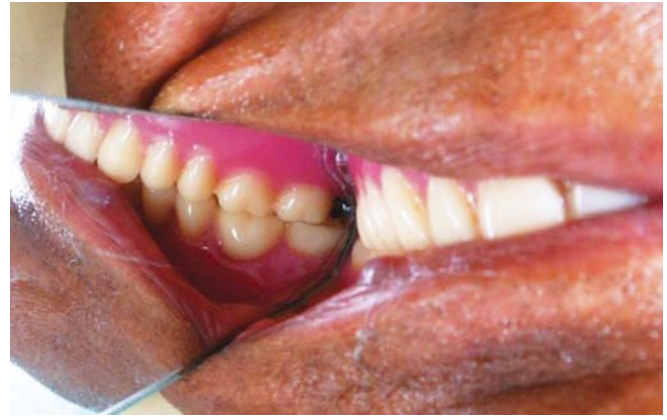

Fig. 10: Final denture insertion done

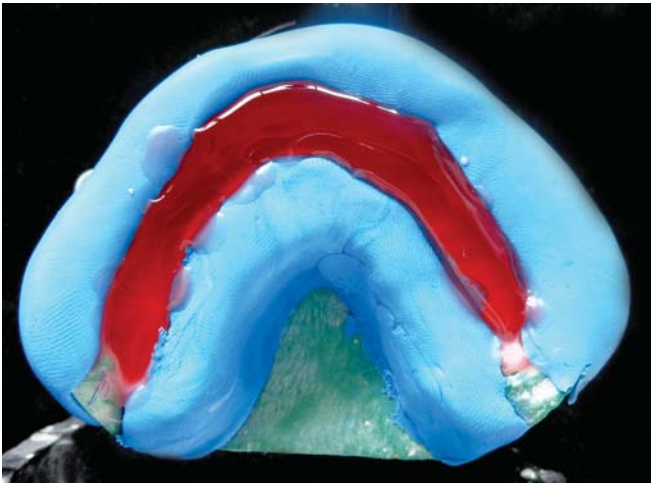


Fig. 8: Dam was removed and void was filled with molten wax to obtain a wax rim

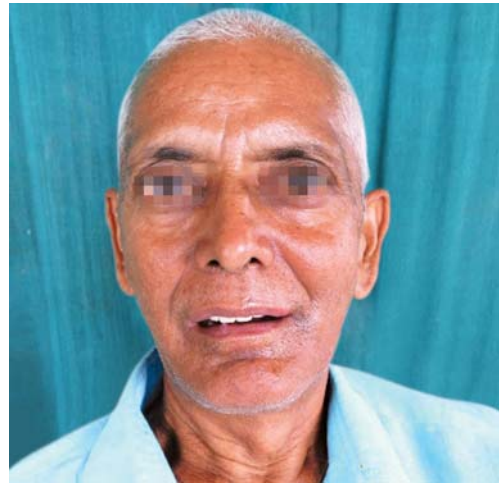

Fig. 11: Patient's esthetics improved drastically

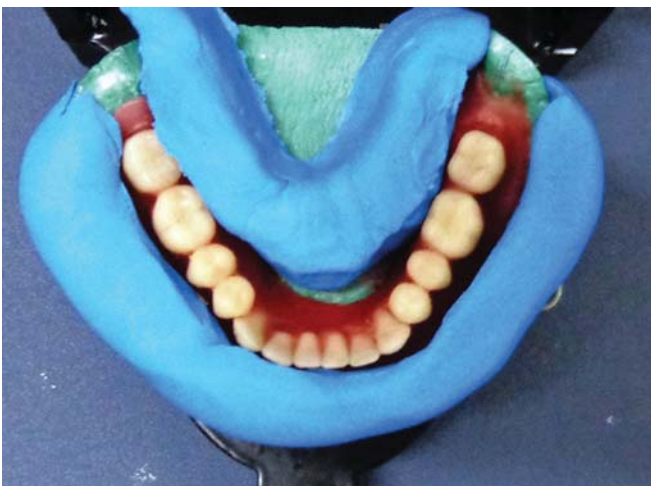

Fig. 9: Posterior teeth arranged according to newly obtained space

comfort and confidence. It results in creating favorable contours on the polished surfaces, especially for lower complete dentures. When bone resorption is significant, as generally noted in elderly patients, this technique allows for functional stability and facilitates adaptation to the new prosthesis.

Thus, it can be concluded that providing a lower denture with a piezographically produced lingual surface enhances its retentive ability over a conventional design. It seems reasonable to maximize the retentive potential with oblique sublingual polished surfaces and minimize the adaptive demand, particularly for older patients, by using a piezographic technique which not only 'customizes' contours and precludes overextension, but also helps arrange teeth for maximum comfort, function and esthetics.

REFERENCES

1. Fish EW. Principles of full denture prosthesis (1st ed). London: John Bale Sons and Danielson 1933:55-56.
2. Klein P. Piezography: Dynamic modeling of prosthetic volume. Actual Odontostomatol (Paris) 1974;28:266-76.
3. Monteith B. Evaluation of a cephalometric method of occlusal plane orientation for complete dentures. J Prosthet Dent 1986;55: 64-69.
4. Mersel A. Morphologic comparison of two neutral zone impression techniques: A pilot study. Gerodontology 1989;8(3): 79-81.
5. Lott F, Levin B. Flange technique: An anatomic and physiologic approach to increased retention, function, comfort, and appearance of dentures. J Prosthet Dent 1966;16:394-413.

6. Barrenas L, Odman P. Myodynamic and conventional construction of complete dentures: A comparative study of comfort and function. *J Oral Rehabil* 1989;16:457-65.
7. Fahmy FM, Kharat DU. A study of the importance of the neutral zone in complete dentures. *J Prosthet Dent* 1990;64:459-62.
8. Beresin VE, Schiesser FJ. A study of the importance of the neutral zone in complete dentures. *J Prosthet Dent* 1991;66:718.
9. Lear CS, Flanagan JB Jr, Moorrees CF. The frequency of deglutition in man. *Arch Oral Biol* 1965;10:83-100.
10. Eibling DE, Cavo JW Jr. Dysphagia. In: Calhoun K, Eibling DE, Wax MK. *Expert guide to Otolaryngology*. Philadelphia: American College of Physicians 2001:282.
11. Ikebe K, Okuno I, Nokubi T. Effect of adding impression material to mandibular denture space in piezography. *J Oral Rehabil* 2006;33:409-15.
12. Morikawa M, Ryo S, Shimizu T, Yasumoto K, Toyoda S. Reproducibility of the neutral zone recording on the estimated occlusal plane. *J Kyushu Dent Soc* 1983;37:945-63.
13. Fahmy FM. The position of the neutral zone in relation to the alveolar ridge. *J Prosthet Dent* 1992;67:805-09.
14. Miller P, Monteith B, Heath MR. The effect of variation of the lingual shape of mandibular complete dentures on lingual resistance to lifting forces. *Gerodontol Assoc* 1998;15(2): 113-19.

ABOUT THE AUTHORS

Jayanta Bhattacharyya (Corresponding Author)

Professor and Head, Department of Prosthodontics, Crown and Bridge
Guru Nanak Institute of Dental Sciences and Research, Kolkata, West
Bengal, India, e-mail: drjb68@gmail.com

Preeti Goel

Senior Lecturer, Department of Prosthodontics, Crown and Bridge
Guru Nanak Institute of Dental Science and Research, Kolkata, West
Bengal, India

Soumitra Ghosh

Reader, Department of Prosthodontics, Crown and Bridge, Guru Nanak
Institute of Dental Sciences and Research, Kolkata, West Bengal, India

Samiran Das

Professor, Department of Prosthodontics, Crown and Bridge, Guru
Nanak Institute of Dental Sciences and Research, Kolkata, West
Bengal, India

Retreatment of Silver Point Obturation: A Case Report and an Overview

Shikha Gulati, MV Sumanthini, Vanitha Shenoy

ABSTRACT

Clinicians frequently encounter endodontically treated teeth that contain silver points within their roots. If endodontic treatment is failing, the need arises to remove this metallic obstruction to facilitate successful nonsurgical retreatment. For the retrieval of these obstructions, most of the methods suggest creating and enlarging a space around the obstruction to loosen it before its retrieval. A large number of removal techniques exists including use of a variety of appropriate burs, specialized forceps, ultrasonic instruments in direct or indirect contact, peripheral filing techniques in the presence of solvents, chelators, or irrigants and microtube delivery using mechanical, adhesion techniques. This case report involves the use of several Hedstrom files, inserted and twisted along the length of silver point to entangle the point and withdraw it, with an overview of other techniques of removal of silver point.

Keywords: Retreatment, Canal obstruction, Retrieval, Silver point removal, Bleaching.

How to cite this article: Gulati S, Sumanthini MV, Shenoy V. Retreatment of Silver Point Obturation: A Case Report and an Overview. *J Contemp Dent* 2012;2(3):114-118.

Source of support: Nil

Conflict of interest: None declared

INTRODUCTION

Endodontic obturation with silver points was introduced during the 1930's. Jasper in year 1933 introduced silver point having same diameter as files and reamers.¹ Historically, the use of silver point was popular because of their ease of handling and placement, ductility, radiopacity and some antibacterial property. However, over the past few decades, the use of silver point has dramatically diminished. Silver points do not produce an acceptable three dimensional seal of the root canal system; rather they simply produce a plug in the apical constriction, with poor adaptability to the root canal walls and do not seal the accessory canals that are frequently present. Also, silver points corrode over time which again compromises the apical seal.² The fact remains that inspite of the disadvantages of silver points they are still in use and clinicians frequently encounter endodontically treated and failed teeth that contain silver points within their roots.

In failing root canal cases, it is of foremost importance to differentiate silver point obturation from gutta percha obturation radiographically, wherein, silver point appears parallel over its length and more radiopaque than gutta percha.¹ When the elected treatment plan is endodontic nonsurgical retreatment, then the goal is to access the pulp

chamber, remove material from root canal system, reshape and clean the canal and obturate with gutta percha.

There has been rapid advancement in endodontic retreatment in recent years. Currently, there are various techniques available to remove silver point or any other metallic obstructions, which are encountered in the root canal. It includes use of a variety of appropriate burs, specialized forceps, ultrasonic instruments in direct or indirect technique, peripheral filing technique in presence of solvents, chelators, or irrigants and microtube delivery using mechanical adhesion techniques.³

The case report describes the nonsurgical retreatment of a maxillary central incisor obturated with silver point and illustrates a few silver point removal techniques.

CASE REPORT

A 24-year-old female patient reported to the Department of Conservative Dentistry and Endodontics with a chief complaint of mild pain and discoloration in maxillary front tooth since 1 month and gave history of root canal treatment done 1 year ago. Clinical examination revealed that the right maxillary central incisor (tooth no 11) was tender on percussion, slightly discolored, periodontal probing within normal limits (<3 mm) and no mobility. Fractured and discolored composite resin restorations were observed on the mesial surfaces of 11 and 21 (maxillary left central incisor), as shown in Figure 1. Preoperative radiograph revealed silver point obturation and thickening of periodontal ligament space in 11 (Fig. 2).

Based on clinical and radiographic examination, a diagnosis of chronic apical periodontitis was made. Patient's

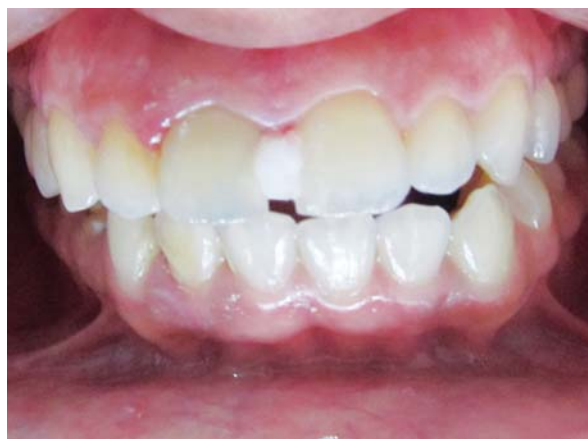

Fig. 1: Preoperative photograph showing faulty composite resin restoration on mesial surface of 11 and 21 and discolored 11

medical history was noncontributory. Nonsurgical endodontic retreatment followed by walking bleach was recommended. During all steps of treatment, tooth was isolated with rubber dam.

Under rubber dam isolation coronal restoration was removed with high speed handpiece taking care not to damage the coronal aspect of silver point. Once proper access was established, it was flooded with gutta percha solvent (Xylene, Dentsply Maillefer DMS IV, Dentsply Maillefer Ballaigues, Switzerland) to soften or dissolve the sealer, which enabled easier removal of silver point. A no 10 stainless steel K-file (MANI, INC. Japan) was used to carry solvent down along the length of the silver point to dissolve as much sealer as possible. Fresh solvent was then introduced. It was repeatedly done, since fresh solvent enhances the efficiency of sealer removal. After thorough removal of sealer, three #10 Hedstrom files (MANI INC. Japan) were inserted down along the silver point as apically as possible in mesial, distal and labial areas. The files were then twisted around one another to entangle the silver point and withdrawn as one unit (Figs 3 and 4). Confirmatory radiograph was taken to check the complete removal of silver point (Fig. 5).

The root canal was then cleaned and shaped with 2% K and H hand files with step back technique to master apical file (MAF) no 45 K-file. Canal was intermittently irrigated with 2.5% sodium hypochlorite (Prime Dental Products, Thane, India). Calcium hydroxide (Deepashree Products, Ratnagiri, India) and chlorhexidine (Vishal, V-concept Dentocare Pvt Ltd, Ahmedabad, Gujarat, India) were mixed to obtain workable consistency and densely packed inside the root canal. Tooth was then temporized with zinc oxide eugenol cement (Deepak Enterprise, Mumbai, India). At the 1 week recall, patient was asymptomatic and tooth was obturated with gutta-percha (Dentsply Maillefer, Ballaigues, Switzerland) and AH plus sealer (Dentsply Maillefer Dentsply, Konstanz, Germany) by lateral condensation

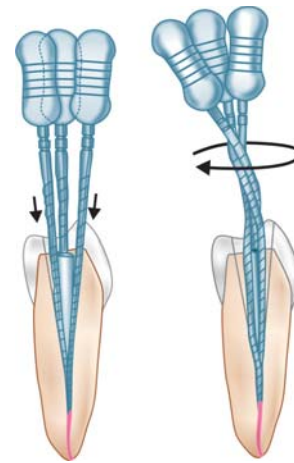


Fig. 3: Braiding technique
(Courtesy: Ingle JI, Bakland LK, Endodontics (5th ed). Hamilton, London: BC Decker Inc 2002;648)

technique followed by temporization with zinc oxide eugenol cement (Fig. 6).

In the subsequent visit, nonvital tooth bleaching was initiated to treat the discoloration. Preoperative color of the tooth was recorded (A3) using shade guide (VITA, Bad Sackingen, Germany), as it provides a point of reference for future comparison. Gutta-percha was removed 2 mm below the cemento-enamel junction and a barrier of zinc polycarboxylate cement (Ploy-F, Dentsply Maillefer, Ballaigues, Switzerland) was placed (Figs 7A and B). Sodium perborate was mixed with 30% hydrogen peroxide (Merck Specialities Pvt Ltd, Mumbai, India) in a clean dappen dish to obtain a thick paste. The paste was carried into the pulp chamber with a plastic filling instrument taking care to cover the entire facial surface of the pulp chamber with the paste. Tooth was then sealed with interim restorative material (Dentsply, Milford, USA). The procedure was repeated twice with a gap of 1 week. It was observed that the color of the tooth changed from shade A3 to A2. It was decided to stop the bleaching procedure as tooth color was similar to the adjacent teeth. Residual peroxides from

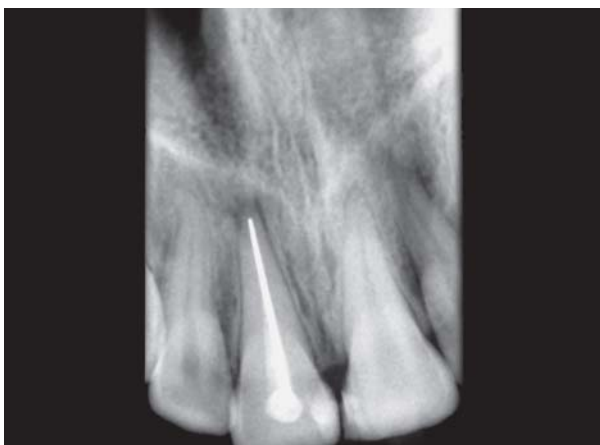

Fig. 2: Preoperative radiograph showing silver point obturation and thickening of periodontal ligament space in 11



Fig. 4: Silver point removed from the root canal

bleaching agent (mainly hydrogen peroxide) can affect the bonding strength of composite resins. Therefore, tooth was sealed with interim restorative material and patient was recalled after 3 weeks. During the following visit, fractured composite resin restoration on the mesial of 21, and access cavity space and mesial of 11 were restored with composite resin (Dentsply Ceram x Duo, Konstanz, Germany) as

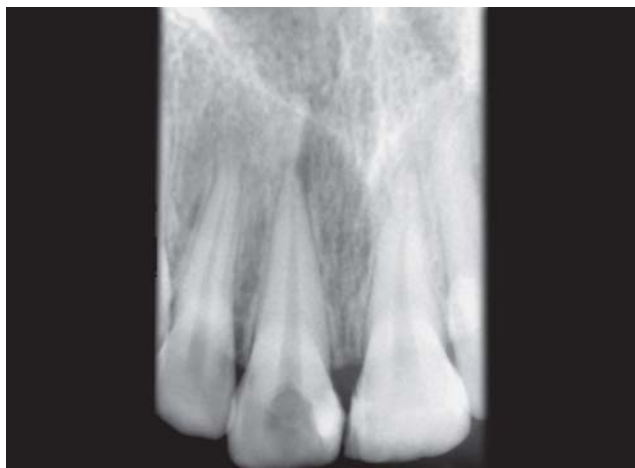

Fig. 5: IOPA radiograph confirming removal of silver point

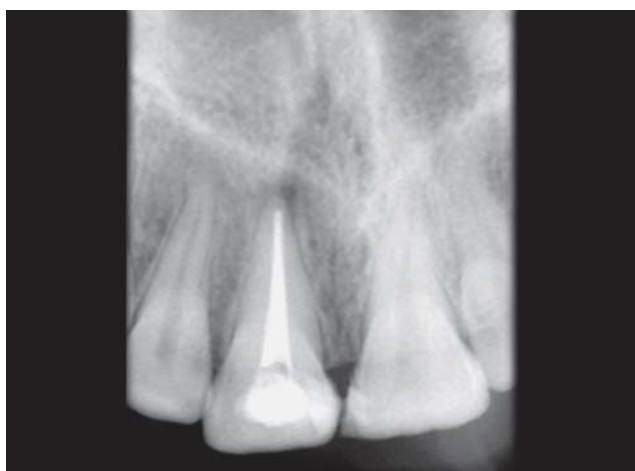
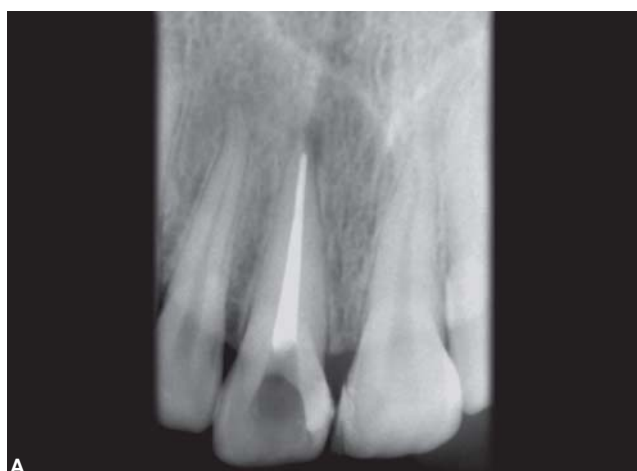
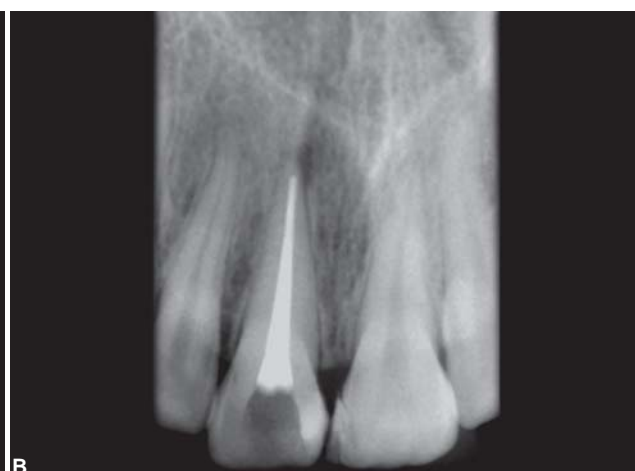Fig. 6: Eleven obturated with gutta-percha and AH Plus sealer



A



B

Figs 7A and B: 2 mm of coronal GP was removed and space restored with zinc polycarboxylate cement

shown in Figure 8. Radiograph was taken to confirm the density of composite resin (Fig. 9). At the 3-month follow-up, patient was asymptomatic and periapical radiograph showed signs of healing (Fig. 10).

DISCUSSION

Silver points lack plasticity to flow and conform to the shape of the root canal system. It is one of the reasons for diminished use of silver points from last few decades. There are some additional clinically practical problems with the use of silver point: (i) Post and core build up becomes impossible with intact silver point, necessitating retreatment and replacement of the points with another material. (ii) Apical surgery becomes more complicated due to differences encountered when attempting a root end preparation in canals that are filled with metal. (iii) Corrosion products, which cause argyrosis and periradicular inflammation, have the potential to induce inflammatory root resorption.⁴ Silver points corrode in the presence of tissue fluids and certain chemicals used during endodontic treatment, which includes sodium hypochlorite and some sealers. The corrosion byproducts such as silver sulfide, silver sulfate, silver carbonate, silver amine hydrate can cause staining of the tooth structure.² Though literature supports the decreased usage of silver point, yet it is in clinical usage because of its ease of handling and placement, ductility, radiopacity and some antibacterial activity. With the introduction of these rigid silver cones it became possible to easily place them to length even in curved, narrow canals with little preparation. This resulted in clinicians often failing to properly clean and shape the canal before obturation. Therefore, treatment failures were mainly the result of the leakage and the failure to remove the irritants from the root canal system.²

Silver point canal preparation techniques produce a relatively parallel preparation in the apical 2 to 3 mm of the

canal, and flared coronal to this apical zone. When clinicians evaluate silver point failures and subsequent retreatment strategies, they should recognize that the silver point have minimal taper and are smooth sided. In a coronally shaped canal, one may take advantage of this available space when approaching retreatment.¹

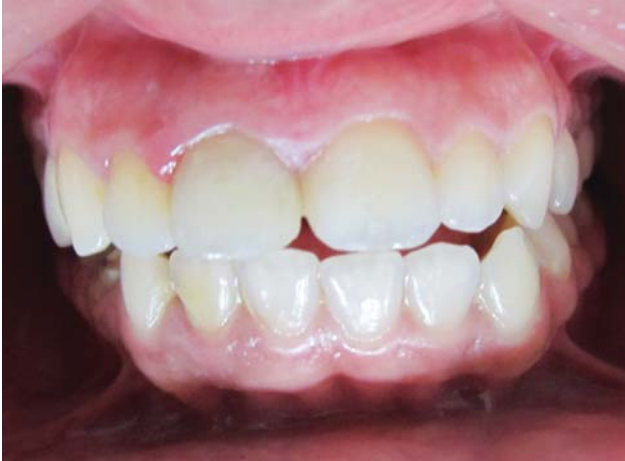

Fig. 8: Postoperative photograph showing effect of bleaching on 11 and composite resin build up on mesial surface of 11 and 21

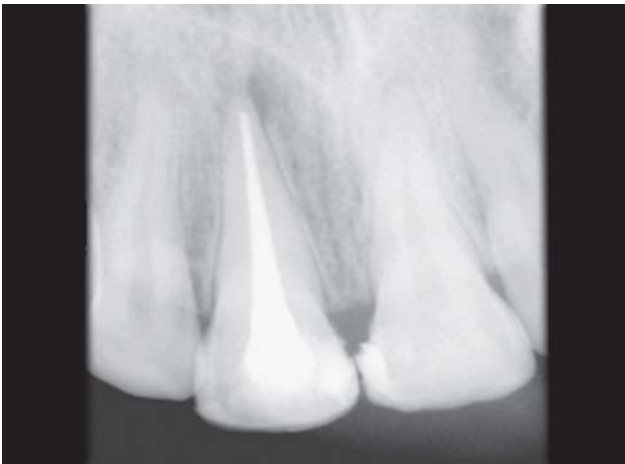

Fig. 9: Postoperative radiograph

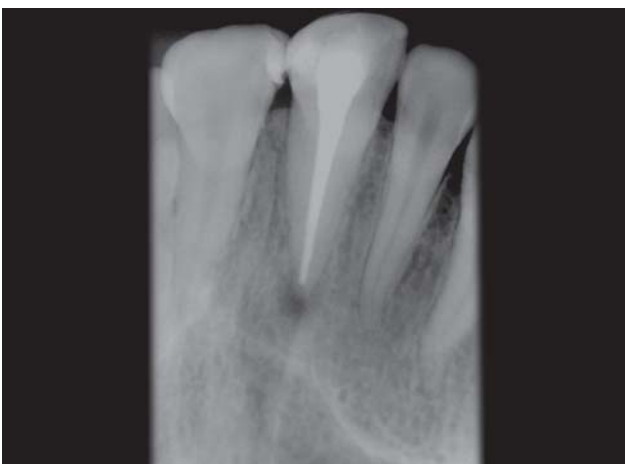

Fig. 10: Three-month follow-up radiograph showing signs of healing

During retreatment of silver point obturated root canals, immediate removal of the silver points should never be attempted. Even if a silver point appears to be poorly adapted to the coronal two-thirds of the canal, it may fit well in the apical third. Silver points will often be affected by corrosion and can be quite fragile. Grasping the coronal aspect of a silver point, without any preparation to loosen it, risks fracturing the silver point.⁵

No standardized procedure for the successful removal of silver point in the canal exists, rather there are various techniques and devices that are established, and are used according to the situation. Braiding technique, involves the use of several Hedstrom files inserted along the length of the silver point and the files are twisted to grasp the silver point and then withdrawn as one unit.⁶ If the point is protruding into the pulp chamber then a sharp spoon excavator or curette can be used to loosen point from seat. A more efficient spoon excavator has been marketed by Stardent with a triangular notch cut out in the tip of the blade (Fig. 11). Specially designed pliers (Stieglitz pliers) can also be used to grasp and retrieve the partially exposed silver point.¹

Ultrasonic instruments can also be used for silver point removal. However, if ultrasonic instruments are applied directly to the silver point, the portion in contact may be shredded, leaving a smaller segment to work with because elemental silver rapidly erodes during mechanical manipulation.² If the silver point resists removal, ultrasonic vibrations can be applied indirectly. Placing a fine Hedstrom file down into the canal alongside the silver point, the file is then activated by ultrasonics (Fig. 12). It will loosen the obstruction and thus silver point can be retrieved. The clinician should always work at the lowest power setting that will efficiently and safely accomplish the clinical task.

A technique as devised by Rowe, uses cyanoacrylate glue (Permabond or Super Glue #30) and hypodermic needles to retrieve silver point.¹ According to it, when a silver point is not protruding into the pulp chamber then select a hypodermic needle that fits snugly over silver point. Remove the bevel of needle and cement it over the silver point using cyanoacrylate glue. After 5 minutes of setting time, the needle is grasped with hemostat and silver point worried from place (Fig. 13A). A variation of this method uses a larger gauge needle and a small Hedstrom file.¹ The piece of blunted needle is placed over the butt end of the silver point. The file is then inserted down the inside of the needle and wedged tightly into the space between (Fig. 13B). Technique using orthodontic ligature wire and plastic tubing can also be used. In this, a groove is cut around the protruding butt end of the silver point with a half round or wheel bur. The ligature wire is then doubled over, and the

two free ends are passed through the tubing to form a loop at the end. The groove in the silver point is then lassoed with the wire loop, which is cinched up tight with the plastic sleeve. Adding a drop of cyanoacrylate cement may improve the grip.¹ The tubing is tightly grasped with pliers or a hemostat and the point is worked loose (Fig. 13C).

Silver points were designed to correspond to the last file size used in the preparation, to presumably fill the canal precisely in all dimensions. Because of the complexity of shape of the root canals, this is fallacious; it is impossible to predictably prepare canals to a uniform size and shape. Although the short term sealability success of silver points seemed comparable to that of gutta-percha, silver points are a poor long-term choice as routine obturating material.

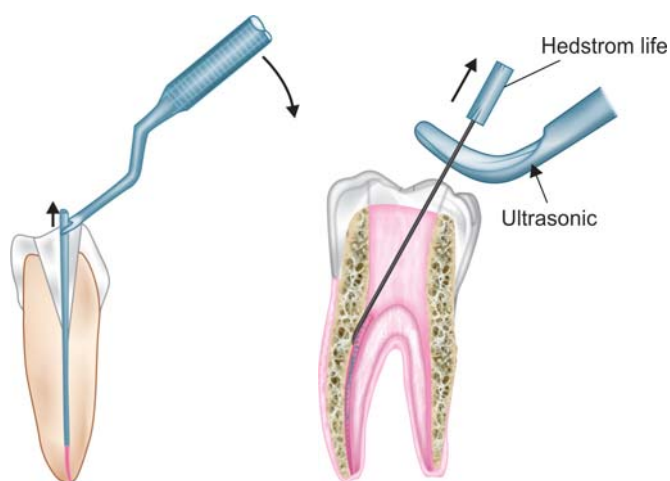
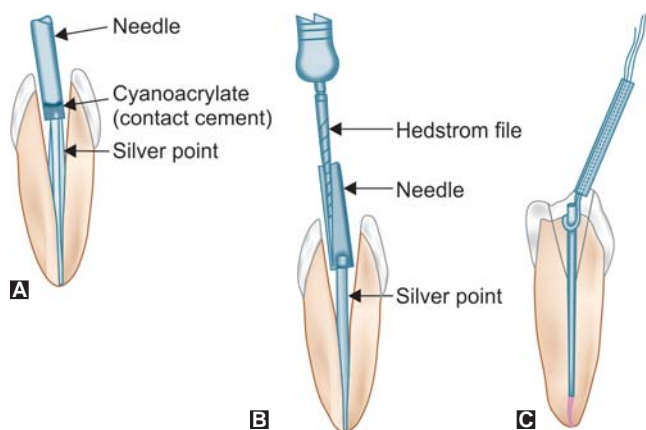


Fig. 11: Silver point removal technique using spoon excavator with a triangular notch cut (Courtesy: Ingle JI, Bakland LK, Endodontics (5th ed). Hamilton, London: BC Decker Inc 2002; 648)

Fig. 12: Use of ultrasonics to remove silver point (Courtesy: Ingle JI, Bakland LK, Endodontics (5th ed). Hamilton, London: BC Decker Inc 2002;649)



Figs 13A to C: Demonstrating different techniques of silver point removal, using (A) cyanoacrylate glue and hypodermic needle, (B) larger gauze needle and H-file, (C) orthodontic ligature wire and plastic tubing (Courtesy: Ingle JI, Bakland LK, Endodontics (5th ed). Hamilton, London: BC Decker Inc 2002;648)

Their major problems relate to nonadaptability and toxicity from corrosion. Also, because of their tight frictional fit and hardness, silver cones are difficult to remove totally or partially. Also, if silver cones are contacted with a bur, their seal may be broken.⁷ Hence, their use should be avoided when better alternatives such as gutta-percha and Resilon root filling techniques are available which do not have the above cited disadvantages.

CONCLUSION

Silver points do not adequately seal the apical foramen. These points corrode over time and allow high levels of leakage. Consequently, the use of silver points in root canal therapy exhibits a relatively high degree of failure, which often necessitates the retreatment of the affected tooth. Occasionally, if the silver points cannot be grasped, retrieval of the point is impossible which remarkably decrease the prognosis. Therefore, silver points are contraindicated as an obturating material in clinical practice.

REFERENCES

1. Ingle JI, Bakland LK. Endodontics (5th ed). Hamilton, London: BC Decker Inc 2002;645-49.
2. Cohen S, Hargreaves K. Pathways of the Pulp (9th ed). St Louis, Missouri: Elsevier Mosby 2006;522-24.
3. Nehme WB. Elimination of intracanal metallic obstructions by abrasion using an operational microscope and ultrasonics. J Endod 2001;27(5):365-67.
4. Ruddle CJ. Nonsurgical retreatment: Review. J Endod 2004;30(12):827-45.
5. Ruddle CJ. Microendodontic nonsurgical retreatment: Silver point removal. Dent Today 1997 Feb;16(2):64-69.
6. Removal of separated files from root canals with a new file removal system: Case reports. J Endod 2006;32(8):789-97.
7. Walton RE, Torabinejad M. Principles and Practice Endodontics (3rd ed). Philadelphia: Elsevier Saunders 2002;240-67.

ABOUT THE AUTHORS

Shikha Gulati (Corresponding Author)

Postgraduate Student, Department of Conservative Dentistry and Endodontics, MGM Dental College and Hospital, Navi Mumbai Maharashtra, India, e-mail: vkshikha@gmail.com

MV Sumanthini

Professor, Department of Conservative Dentistry and Endodontics MGM Dental College and Hospital, Navi Mumbai, Maharashtra, India

Vanitha Shenoy

Professor and Head, Department of Conservative Dentistry and Endodontics, MGM Dental College and Hospital, Navi Mumbai Maharashtra, India

Oral Mucocele: Review and Case Report

Mihir Jha, Vivek Jogani

ABSTRACT

Mucocele is a common lesion of the oral mucosa that results from an alteration of minor salivary glands due to a mucous accumulation. Two histological types exist—extravasation and retention. Mucoceles can appear at any site of the oral mucosa where minor salivary glands are present. Diagnosis is principally clinical; therefore, the anamnesis should be carried out correctly, looking for previous trauma. The most common location of the extravasation mucocele is the lower lip, while retention mucoceles can be found at any other site. Mucoceles can affect the general population, but most commonly young patients (20-30 years old). Clinically they consist of a soft, bluish and transparent cystic swelling which normally resolves spontaneously. Treatment frequently involves surgical removal. Nevertheless micromarsupialization, cryosurgery, steroid injections and CO₂ laser are also described.

Keywords: Mucocele, Mucocele treatment, Minor salivary glands.

How to cite this article: Jha M, Jogani V. Oral Mucocele: Review and Case Report. *J Contemp Dent* 2012;2(3):119-124.

Source of support: Nil

Conflict of interest: None declared

INTRODUCTION

The term ‘mucocele’ is used to define the accumulation of mucous secreted from salivary glands and their ducts in the oral cavity’s subepithelial tissue.¹ Mucocele is a common lesion of the oral mucosa that results from an alteration of minor salivary glands due to a mucous accumulation causing limited swelling.² They appear as fluctuant, bluish, nontender, submucosal swelling with a normal overlying mucosa. Two types of mucocele can appear—extravasation and retention. Extravasation mucocele results from a broken salivary glands duct and the consequent spillage into the soft tissues around this gland.³ Retention mucocele appears due to a decrease or absence of glandular secretion produced by blockage of the salivary gland ducts.⁴ Although minor salivary glands are found in most parts of the oral cavity except the gingiva, mucoceles occur most commonly in the lower lip, probably due to the higher incidence of mechanical trauma in this region.³ When located on the floor of the mouth these lesions are called ranulas because the inflammation resembles the cheeks of a frog.⁵ Mucocele is a common lesion and affects the general population. For this reason we felt it would be interesting review the clinical characteristics of mucoceles, and their treatment and evolution in order to aid decision making in daily clinical practice.

ETIOPATHOLOGY

Etiology

1. *Trauma:* Minor trauma and lacerations, sharp tooth, overhanging restorations, prosthetic appliances.⁶
2. Incorrect use of pacifiers is common among children. During the tooth eruption period, the oral tissues become very sensitive and children try to relieve the eruptive symptoms by biting the pacifier with exaggerated force and sometimes in the wrong place, leading to the development of a wide spectrum of pathologies.⁷
3. Involuntary sucking through sites of edentulous space.⁸
4. Congenital.⁸

Yamasoba et al⁹ highlight two crucial etiological factors in mucoceles, traumatism and obstruction of salivary gland ducts. Mucous is produced exclusively by the minor salivary glands and is also the most important substance secreted by the major sublingual salivary glands. Mucoceles can appear by an extravasation or a retention mechanism. Extravasation mucoceles are caused by a leaking of fluid from surrounding tissue ducts or acini. This type of mucocele is commonly found on the minor salivary glands. Physical trauma can cause a leakage of salivary secretion into surrounding submucosal tissue. Inflammation becomes obvious due to stagnant mucous resulting from extravasation.⁵ A study by Bagán et al² considering 25 mucoceles suffered in the general population, showed that 5% were retention mucoceles, whereas the other 95% were extravasation. They proposed that extravasation mucoceles undergo three evolutionary phases.

In the first phase, mucous spills diffusely conjunctive tissues where some leukocytes and histiocytes are found.

Granulomas appear during the resorption phase due to histiocytes, macrophages and giant multinucleated cells associated with a foreign body reaction.

In the final phase connective cells form a pseudocapsule without epithelium around the mucosa. Retention mucoceles are formed by dilation of the duct secondary to its obstruction or caused by a sialolith or dense mucosa. The majority of retention cysts develop in the ducts of the major salivary glands.⁵

CLINICAL CHARACTERISTICS

The incidence of mucoceles is generally high, 2.5 lesions per 1,000 patients, frequently in the second decade of life¹⁰⁻¹² and rarely among children under 1 year of age with

no gender predilection.^{2,9,10,13,14} A clinicopathologic study of 138 cases of mucocele showed the percentage prevalence of mucocele in children to be 24.5%, similarly a Brazilian study has shown it to be around 36%.^{3,6} The usual clinical history is one of a painless swelling, often recurrent in nature, that may be present for months or even years before the patient seeks treatment.³ Mucoceles present a bluish, soft and transparent cystic swelling which frequently resolves spontaneously with no clinical difference between extravasation and retention type. The blue color is caused by vascular congestion, and cyanosis of the tissue above and the accumulation of fluid below. Coloration can also vary depending on the size of the lesion, proximity to the surface and upper tissue elasticity.^{5,11,15} Lesion duration is not constant, from a few days to 3 years.⁹ Bagán et al provide a study of 25 patients suffering from mucoceles. A total of 48% of the patients became aware of their lesion on seeing it although there were no symptoms. In the case of another 48%, lesions were found by a specialist by chance. Only 4% patients had some unspecified feeling of discomfort but no real pain.² Mucoceles of the minor salivary glands are rarely larger than 1.5 cm in diameter and are always superficial. Mucoceles found in deeper areas are usually larger. Mucoceles can cause a convex swelling depending on the size and location, as well as difficulties in speaking or chewing.⁵ Mucoceles can appear at any site of the oral mucosa containing salivary glands.¹⁶ Extravasation mucoceles appear frequently on the lower lip whereas retention mucoceles appear at any other location of the oral cavity. The lower lip is the most frequent site for a mucocele as it is the most probable place for a trauma, especially at premolar level. A study of 312 patients showed 230 lesions on the lower lip (73.7%), with the tongue as the second most common location (15.4%)⁹ followed by the buccal mucosa and palate; and are rarely found in the retromolar region and posterior dorsal area of the tongue.^{12,17} Occasionally mucoceles can involve the glands of Blandin-Nuhn.⁵ These glands are located on the muscle of the ventral side of the tongue; the histological diagnosis is always extravasation type, and normally affecting young patients.^{10,15}

CASE REPORT

A 8-year-old female child visited the Department of Pedodontics, MGM Dental College and Hospital, Navi Mumbai, Maharashtra, India, with the chief complaint of swelling on the left side of lower lip (Fig. 1). The history of present illness consisted of swelling in the lower lip since 2 to 3 months in the inner aspect of lower lip in the left lateral incisor region. A detailed history elicited from the

accompanying parent showed etiology to be trauma from lip biting. The mother also gave the history of previous similar swellings which were surgically excised. The swelling was already surgically excised twice in a span of 1 year before the child visited our department.

The child was observed nonchalantly to see whether lip biting or sucking is present as a habit. Examination of the swelling showed it to be oval in shape, soft and fluctuant, palpable with no increase in temperature. It was blue in color and symptomless. The lesion was 1.5 cm in diameter and superficially placed in the inner aspect of labial mucosa of the lower lip (Fig. 1). The patient did not have any difficulty in speaking or chewing, there only concern was its repeated occurrence. The child had mixed dentition with minimal calculus and no obvious malocclusion.

DIAGNOSIS

Mucocele presents with obvious diagnosis; therefore, the anamnesis should be carried out correctly, looking for previous trauma. The appearance of mucoceles is pathognomonic^{11,15} and the following data are crucial: Lesion location, history of trauma, rapid appearance, variations in size, bluish color and the consistency.¹⁶ Palpation can be helpful for a correct differential diagnosis. Lipomas and tumors of minor salivary glands present no fluctuation while cysts, mucoceles, abscess and hemangiomas do.¹⁰ Mucoceles are mobile lesions with soft and elastic consistency depending on how much tissue is present over the lesion.¹¹ Despite this fluctuation, a drained mucocele would not fluctuate and a chronic mucocele with a developed fibrosis would have less fluctuation. A simple technique known as fine needle aspiration biopsy (FNAB) is very helpful, especially when differential diagnosis of angiomatous lesions is involved. Abundant mucosa without epithelial components is found within mucoceles as well as

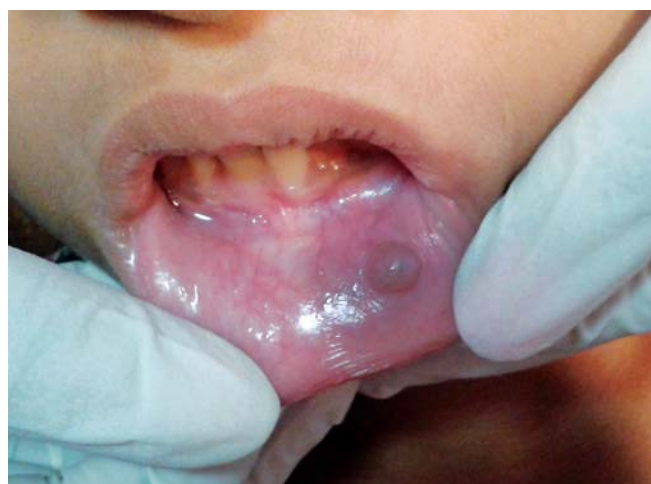

Fig. 1: Lower lip mucocele

many inflammatory cells, especially histiocytes.¹⁸ A histopathologic study (Fig. 2) is crucial to confirm the diagnosis and to ensure that glandular tissue is completely removed. Two types of mucoceles exist: Retention mucoceles and extravasation mucoceles. In the case of retention mucoceles a cyst cavity can be found, this is generally well defined with an epithelial wall covered with a row of cuboidal or flat cells produced from the excretory duct of the salivary glands.⁵ Compared to extravasation mucoceles, retention mucoceles show no inflammatory reaction and are true cysts with an epithelial covering.¹⁰ Extravasation mucoceles are pseudocysts without defined walls. The extravasated mucous is surrounded by a layer of inflammatory cells and then by a reactive granulation tissue made up of fibroblasts caused by an immune reaction. Even though there is no epithelial covering around the mucosa, this is well-encapsulated by the granulation tissue.^{4,5,10}

In the present case, the history given by patient clearly directed it to be a mucocele and only. Presurgical blood investigations were conducted and the values were found to be normal (Hb: 13 gm%, BT: 2 minutes, CT: 6 to 10 minutes, TLC: 7,200/cm).

Final Diagnosis

Extravasation mucocele associated with lower lip biting after histopathological examination of the tissue.

TREATMENT

Generally, small and superficial mucoceles do not require treatment because they often heal after spontaneous rupture. However, in most cases, the treatment of choice is excision. The lesions can be completely excised, including the associated salivary gland tissue as well as any marginal glands, before primary closure, reducing the incidence of recurrence.³ With a simple incision of the mucocele the

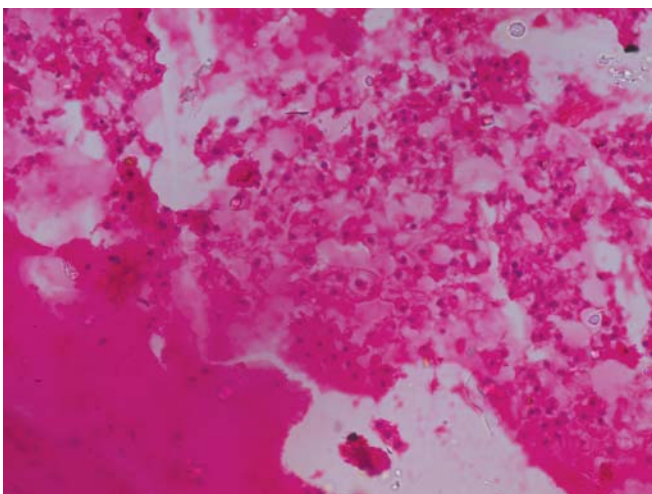


Fig. 2: Histological appearance of the excised mucocele

content would drain out but the lesion would reappear as soon as the wound heals.¹³ There is no need for treatment if superficial extravasation mucoceles resolve spontaneously. Small mucoceles can be removed completely with the marginal glandular tissue before suture. In the case of larger mucoceles, marsupialization would avoid damage to vital structures. Extravasation mucoceles are pseudocysts with an incomplete epithelial covering surrounded by inflammatory elements and granulation tissue. It is important in the case of the retention type to surgically resect the lesion with its epithelial wall to ensure complete removal and reduce chances of recurrence. A simple drainage with a surgical incision has shown recurrence as soon as the wound heals. In certain cases, the extravasation type has shown spontaneous remission due to bursting of the cyst and spilling of its contents, therefore, the incision should not be placed on the most prominent part of the swelling.¹⁹

For the surgical removal of the mucocele, an elliptical incision is the most popular one. This helps to decrease the extent of mucosal tissue loss, decreases the incidence of formation of large fibrous scars and helps to prevent spilling of the cystic content, which could be responsible for its recurrence.¹⁹

In the present case after presurgical cleaning a thin fusiform incision was placed over the center of the lesion. Slowly the flap was dissected or separated from the underlying tissue. The tissue was removed (Figs 3 and 4) in total and the flap was approximated. Primary closure with interrupted suture was done. Incision was placed over the lesion so as to prevent tissue loss which creates problem in primary closure and sometimes require flap reposition. Lesion was sutured and soft diet was advised for a week time and was prescribed with anti-inflammatory. As there was no habit associated there was any need of any appliance to protect the surgical site from healing. The child was observed over a period of 11 months with no recurrence.

DISCUSSION

Mucocele stands out to be one of the most common pediatric oral lesion.³ Propensity of this lesion is more in second decade of life with rare incidence below 1 year of age and with no gender predilection.

In the Minnesota oral prevalence study that included 23,616 white adults older than 35 years of age, mucoceles represented the 17th most common oral mucosal lesion, with a prevalence of 2.4 cases per 1,000 people. Data from the third National Health and Nutrition Examination Survey (NHANES III) that included 17,235 people aged 17 years and older documented an overall prevalence ranking of 44 for the mucocele and a point prevalence of 0.02%.

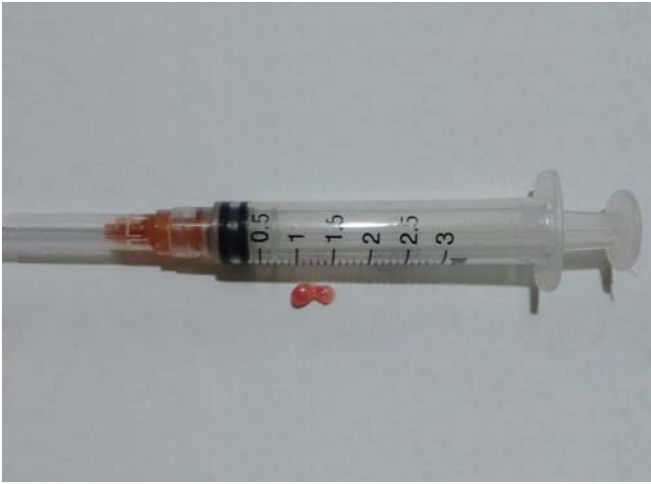

Fig. 3: Excised mucocele

In the same study, which consisted of 10,030 children aged 2 to 17 years, the mucocele had a point prevalence of 0.04%. Congenital mucoceles in newborns are rare, with sporadic case reports and small case series appearing in the literature.³

Mucocele are mainly asymptomatic and is present for long time before diagnosed but in instances when it appears as multiple and recurrent and large in size it may be painful. The lower lip is the most common site, although they can be found in any region where there are salivary glands, but rarely in the palate, retromolar space and the buccal mucosa. The second most common site being ventral surface of tongue which is known as mucocele of Blandin-Nuhn, occurs commonly in younger children.³

The diagnosis is principally clinical with a histopathological examination of the aspirant ruling out chances of hemangioma. The classic characteristics for the differential diagnosis of oral mucocele (OM) are a history of trauma and the rapid appearance of a bluish swelling generally on the lower lip mucosa.⁸ A recent review of 1,824 cases showed the more common etiology being trauma with a periodic history of rupture. Cases reported with no history of trauma have speculated that involuntary sucking of the region may also lead to development of mucocele.⁶⁻⁸

Histologically, mucoceles are currently classified as mucous extravasation or mucous retention phenomenon, depending on the presence of epithelial lining. In the general population, the prevalence of partial or complete epithelial lining surrounding the accumulated saliva is higher than in pediatric patients, ranging from 7 to 22%.^{5,18-21} In children, the low prevalence of MRP, is probably due to the inability of the ductal structures to contain an exaggerated accumulation of secretion. The mucous extravasation phenomenon is the most common type of mucocele in pediatric patients. The physiopathologic process for the formation of this phenomenon was best explained by Shareef et al. The extravasated saliva is first surrounded by

inflammatory cells and then by granulation tissue composed mainly of fibroblasts. Due the absence of epithelial lining, this phenomenon should be categorized as a pseudocyst or false cyst.³

According to Pedron et al the mucocele treatment may be performed by conventional surgery, cryotherapy, and, more recently, laser surgery and laser vaporization.⁶ Small mucoceles can be removed completely with the marginal glandular tissue before suture. In the case of larger mucoceles, marsupialization would avoid damage to vital structures. Clinically there is no difference between both types of mucocele, and are therefore treated in the same manner. Nevertheless when an obstruction of retention mucoceles is detected treatment involves the removing the top of the cyst and introducing a lacrimal catheter into the duct to dilate it.⁵ A study of 14 pediatric patients describes micromarsupialization techniques with 85% success.²⁰ The aim of this technique is to drain the mucous and reduce the size of the lesion. This technique (after disinfection and anesthesia) consists of passing thick silk thread through the lesion at its largest diameter and then making a surgical knot. The suture is removed after 7 to 10 days, enough time for the mucocele to disappear. This technique has the advantage of being simple, relatively painless and with minimum trauma.²⁰

Some studies have reported using cryosurgery in treating mucoceles with encouraging results.^{21,22} Cryotherapy is well received by patients due to a relative lack of discomfort, the absence of bleeding and minimal to no scarring.⁴ Clinical advantages include the ease of application, preservation of inorganic structure of bone and very low incidence of infection. In one study, 36 mucoceles were removed using cryosurgery and only two lesions reappeared (5.6%).²³ Increased permeability and edema within 1 to 6 hours postoperatively following cryotherapy.²⁴ An additional feature of oral cGVHD is the development of recurrent

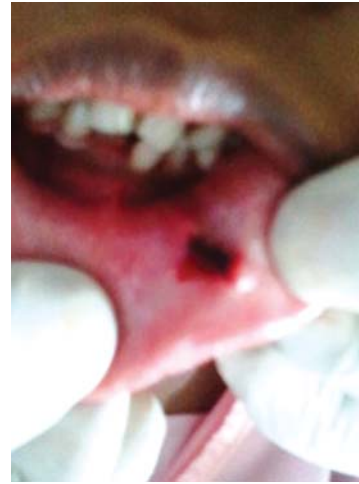

Fig. 4: Surgical area after mucocele resection

superficial mucoceles. These are generally painless mucous filled blisters that develop primarily on the palate, but can also be observed on the labial and buccal mucosa and tongue, or wherever there are minor salivary glands. Some authors have also suggested using intralesional steroid injections in such cases.²⁵

CO₂ laser has a high water absorption rate and is well-absorbed by all soft tissues with high water content. In addition, its effects on adjacent tissues are minimal. These properties make CO₂ laser the perfect surgical treatment for oral soft tissues.²⁶ The cut is precise and does not affect the muscle layer, causes minimal hemorrhage and almost no acute inflammatory reaction. The operation time is short (3-5 minutes) making it a convenient treatment for children and patients who cannot withstand long treatment.^{13,27} Huang et al in a study of 82 patients suffering from mucoceles on the lower lip treated with CO₂ laser observed that two lesions reappeared afterwards and one patient suffered temporary paresthesia.¹³ In another study of 68 patients, 30 were treated with CO₂ laser, only one lesion reappeared and there were no postoperative complications. Vaporization with argon and Nd:YAG lasers have been described for the treatment of mucoceles. Both lasers procedures presented satisfactory results with low recurrence rates and were well-tolerated by the patients, whose discomfort was the main complaint reported.¹ Treatment of mucoceles with a high-intensity diode laser provided satisfactory results in the two cases presented. As the incidence of mucoceles in children is relatively high, this technique may represent an improvement over other techniques and an adequate protocol for this lesion in a pediatric population. Appropriate power-set parameters must be considered for this type of procedure to avoid excessive thermal damage to the soft tissues and consequent unfavorable postoperative symptoms.¹ In contrast, due to the more aggressive process, in the 38 cases removed by scalpel there were nine postoperative complications—a temporary anesthesia in a 2.4 cm diameter mucocele located close to the mental nerve, three cases of postoperative hemorrhage and five patients with fibrous scar tissue after normal healing.¹² The key point in avoiding recurrence is to eliminate the adjacent surrounding glandular acini and removing the lesion down to the muscle layer.^{13,27} Special care should be taken to avoid injury to the adjacent glands and ducts while placing sutures as this is also a cause for reappearance.⁵ Regarding overall recurrence rates, in one study, 70 mucoceles were surgically removed from the lower lip, and two lesions reappeared (2.8%).⁹

CONCLUSION

Mucoceleles are one of the most common lesions seen in oral cavity that cause distress to the patient because of their

malignant appearance. In spite of many treatment options simple surgical excision is the treatment of choice and when done with care is the best treatment alternative that can relieve the patients fear and anxiety.

REFERENCES

1. Pedron GI, Galleta CV, Azevedo HL. Treatment of mucocele of the lower lip with diode laser in pediatric patients: Presentation of two clinical cases. *Pediatr Dent* 2010 Dec;39(7):539-41.
2. Bagán Sebastián JV, Silvestre Donat FJ, Peñarrocha Diago M, Milián Masanet MA. Clinico-pathological study of oral mucoceles. *Av Odontoestomatol* 1990;6:389-91.
3. Martin PS, Santos T, Piva MR, Andrade E. A Clinicopathologic review of 138 cases in pediatric population. *Quint Int* 2001;42(8):679-85.
4. Boneu-Bonet F, Vidal-Homs E, Maizcurrana-Tornil A, González-Lagunas J. Submaxillary gland mucocele: Presentation of a case. *Med Oral Patol Oral Cir Bucal* 2005;10:180-84.
5. Baumash HD. Mucoceles and ranulas. *J Oral Maxillofac Surg* 2003;61:369-78.
6. Tannure NP, Silvia PD, Primo LG, Maia LC. Management of oral mucocele in a 6-month-old child. *Braz J Health* 2010;1:210-14.
7. Alves LA, Nicolo RD, Ramos CJ, Shintome L, Barbosa CS. Retention mucocele of the lower lip associated with inadequate use of pacifier. *Dermatol Online J* 2010;16(7):9.
8. Seo J, Bruno I, Artico G, Vechio AD, Migliari DA. Oral mucocele of unusual size on the buccal mucosa: Clinical presentation and surgical approach. *Open Dent J* 2012;6:67-68.
9. Yamasoba T, Tayama N, Syoji M, Fukuta M. Clinicostatistical study of lower lip mucoceles. *Head Neck* 1990;12:316-20.
10. Guimarães MS, Hebling J, Filho VA, Santos LL, Vita TM, Costa CA. Extravasation mucocele involving the ventral surface of the tongue (glands of Blandin-Nuhn). *Int J Paediatr Dent* 2006;16:435-929.
11. Bentley JM, Barankin B, Guenther LC. A review of common pediatric lip lesions: Herpes simplex/recurrent herpes labialis, impetigo, mucoceles, and hemangiomas. *Clin Pediatr (Phila)* 2003;42:475-82.
12. Yagüe-García J, España-Tost AJ, Berini-Aytés L, Gay-Escoda C. Treatment of oral mucocele-scalpel versus CO₂ laser. *Med Oral Patol Oral Cir Bucal* 2009;14:e469-74.
13. Huang IY, Chen CM, Kao YH, Worthington P. Treatment of mucocele of the lower lip with carbon dioxide laser. *J Oral Maxillofac Surg* 2007;65:855-58.
14. de Camargo Moraes P, Bönecker M, Furuse C, Thomaz LA, Teixeira RG, de Araújo VC. Mucocele of the gland of Blandin-Nuhn: Histological and clinical findings. *Clin Oral Investig* 2009;13:351-53.
15. Tran TA, Parlette HL III. Surgical pearl: Removal of a large labial mucocele. *J Am Acad Dermatol* 1999;40:760-62.
16. Andiran N, Sarikayalar F, Unal OF, Baydar DE, Ozaydin E. Mucocele of the anterior lingual salivary glands from extravasation to an alarming mass with a benign course. *Int J Pediatr Otorhinolaryngol* 2001;61:143-47.
17. Zancopé E, Pereira AC, Ribeiro-Rotta RF, Mendonça EF, Batista AC. Mucocele in posterior dorsal surface of tongue: An extremely rare location. *J Oral Maxillofac Surg* 2009;67:1307-10.
18. Layfield LJ, Gopez EV. Cystic lesions of the salivary glands: Cytologic features in fine-needle aspiration biopsies. *Diagn Cytopathol* 2002;27:197-204.

19. Madan N, Rathnam A. Excision of mucocele: A surgical case report. *Biological and Biomedical Reports* 2012;2(2):115-18.
20. Delbem AC, Cunha RF, Vieira AE, Ribeiro LL. Treatment of mucus retention phenomena in children by the micro-marsupialization technique: Case reports. *Pediatr Dent* 2000;22:155-58.
21. Marcushamer M, King DL, Ruano NS. Cryosurgery in the management of mucoceles in children. *Pediatr Dent* 1997;19:292-93.
22. Gill D. Two simple treatments for lower lip mucocoeles. *Australas J Dermatol* 1996;37:220.
23. Yeh CJ. Simple cryosurgical treatment for oral lesions. *Int J Oral Maxillofac Surg* 2000;29:212-16.
24. Farah CS, Savage NW. Cryotherapy of oral lesions. *Aus Dent J* 2006;51(1):2-5.
25. Luiz AC, Hiraki KR, Lemos CA Jr, Hirota SK, Migliari DA. Treatment of painful and recurrent oral mucoceles with a high-potency topical a corticosteroid: A case report. *J Oral Maxillofac Surg* 2008;66:1737-39.
26. Pick RM, Colvard MD. Current status of lasers in soft tissue dental surgery. *J Periodontol* 1993;64:589-602.
27. Kopp WK, St-Hilaire H. Mucosal preservation in the treatment of mucocele with CO₂ laser. *J Oral Maxillofac Surg* 2004;62:1559-61.

ABOUT THE AUTHORS

Mihir Jha (Corresponding Author)

Senior Lecturer, Department of Pedodontics, MGM Dental College and Hospital, Navi Mumbai, Maharashtra, India
e-mail: drvivekjogani@yahoo.com

Vivek Jogani

Senior Lecturer, Department of Pedodontics, MGM Dental College and Hospital, Navi Mumbai, Maharashtra, India

Submitting a Paper to Journal of Contemporary Dentistry

INSTRUCTIONS TO AUTHORS

The Journal of Contemporary Dentistry publishes original scientific papers, reviews, case reports and method presentation articles in the field of dentistry. Original articles are published in all dentistry-related disciplines, all areas of biomedical science, applied materials science, bioengineering, epidemiology and social science relevant to dental disease and its management. Manuscripts submitted for publication must be original articles and must not have appeared in any other publication. The publisher reserves the right to edit manuscripts for length and to ensure conciseness, clarity and stylistic consistency, subject to the author's final approval.

AUTHORSHIP

Individuals identified as authors must meet the following criteria established by the International Committee of Medical Journal Editors: (1) Substantial contributions to conception and design, or acquisition of data, or analysis and interpretation of data; (2) drafting the article or revising it critically for important intellectual content; and (3) final approval of the version to be published. The number of authors is limited to 6.

ETHICAL GUIDELINES

Experimentation involving human subjects will be published only, if such research has been conducted in full accordance with ethical principles. Manuscripts must include a statement that the experiments were undertaken with the understanding and written consent of each subject and according to the above-mentioned principles, the statement should also state that the protocol was approved by the author's institutional review committee for human subjects or that the study was conducted in accordance with the Helsinki declaration of 1975, as revised in 2000. Do not use any designation in tables, figures or photographs that would identify a patient, unless express written consent from the patient is submitted. When animals are involved, the methods section must clearly indicate that adequate measures were taken to minimize pain or discomfort. Experiments should be carried out in accordance with local laws and regulations.

CLINICAL TRIALS

Report clinical trials using the CONSORT guidelines at www.consortstatement.org. A CONSORT checklist and a flowchart should also be included in the submission material.

Conflict of Interest/Source of Funding: It is necessary that information on potential conflicts of interest be part of the manuscript. The journal requires all sources of institutional, private and corporate financial support for the work within the manuscript to be fully acknowledged and any potential conflicts of interest noted. Please include the information under acknowledgments.

ARTICLE PREPARATION

Original Research

Should describe significant and original experimental observations and provide sufficient detail so that the observations can be critically evaluated and, if necessary, repeated. Articles considered as original research include, randomized controlled trials, intervention studies, studies of screening and diagnostic test, outcome studies, cost-effectiveness analyses, case-control series and surveys with high response rate. Up to 2,500 words, excluding references and abstract.

Short Communication, Short Case Presentations, and Method Presentation Articles

Short Case Presentation: Interesting cases authors would like to share with the readers. Method presentation articles: Must present significant improvements in clinical practice (a novel technique, technological breakthrough or practical approaches to clinical challenges). Up to 1,000 words, excluding references and abstract and up to five references.

Case Reports

New/interesting/very rare cases can be reported. Should have importance and significance. Repetition of well-known and extensively published conditions will not be accepted. Include a thorough literature review and emphasize the clinical relevance. Up to 2,000 words, excluding references and abstract and up to 10 references.

Review Articles

Must have broad general interest. Reviews should take a broad view of the field rather than merely summarizing the authors' own previous work, systemic critical assessments of literature and data sources. Up to 3,500 words, excluding references and abstract.

Letter to the Editor

Should be short, decisive observation. They should not be preliminary observations that need a later paper for validation. Up to 400 words and four references.

ARTICLE SUBMISSION TO THE JOURNAL

Presentation: Clearly convey research findings or clinical reports. Avoid technical jargon, but clearly explain where its use is unavoidable. The background and hypotheses underlying the study as well as its main conclusions should be clearly explained. Titles and abstracts should be written in language readily intelligible.

Abbreviations/Acronyms: Abbreviations should be kept to a minimum, particularly those that are not standard. Terms and names referred to as abbreviations or acronyms should be written out when first used with the abbreviation in parenthesis. Standard units of measurement need not be spelled out.

Names of teeth: The complete names of individual teeth must be given in the text. In tables and figures, individual teeth can be identified using the FDI two-digit system, if full tooth names are too unwieldy.

STRUCTURE

1. **First Page File:** Prepare the title page, covering letter, acknowledgment, etc. All information which can reveal your identity should be here. Include the title of the article and the full name, degrees, title and professional affiliation of every author. Provide the contact details and e-mail address of the corresponding author.
2. **Article File:** The main text of the article, beginning from abstract till references (including tables) should be in this file. Do not include any information, such as acknowledgment, your names in page headers, etc. in this file. Illustrations and tables should be numbered and cited in the text in order of appearance and grouped at the end of the text. High-resolution images must be sent to the managing editor upon article acceptance.
3. **Images:** Submit good quality color images. Submit TIFF/JPEG (photographs) files only.
4. **Legends:** Legends for the figures/images should be included at the end of the article file. Figure legends should begin with a brief title for the whole figure and continue with a short description of each panel and the symbols used; they should not contain any details of methods.
5. **References:** Provided with direct references to original research sources. Note that small numbers of references to key original papers will often serve as well as more exhaustive lists. List references at the end of the article in numeric sequence.

The authors' form and copyright transfer form have to be submitted to the editorial office, in original with the signatures of all the authors.

PREPARATION OF THE MANUSCRIPT

Manuscripts must be submitted in Microsoft Word. Margins should be at least 1" on both sides (top and bottom). Materials should appear in the following order:

- Title page
- Abstract (or introduction) and keywords
- Text
- Footnotes
- Acknowledgment
- References
- Figure legends
- Tables

Figures should not be embedded in the manuscript. Authors should retain a copy of their manuscript for their own records.

The manuscripts should be typed in A4 size (212 × 297 mm) paper, with margins of 25 mm (1 inch) from all the four sides. Use 1.5 spacing throughout. Number pages consecutively, beginning with the title page. The language should be American English.

TITLE PAGE

The title page should carry the following:

1. Type of manuscript
2. The title of the article, which should be concise but informative
3. Running title or short title not more than 50 characters
4. Name of the authors (the way it should appear in the journal), with his or her highest academic degree(s) and institutional affiliation
5. The name of the department(s) and institution(s) to which the work should be attributed
6. The name, address, phone numbers, facsimile numbers and e-mail address of the contributor responsible for correspondence about the manuscript
7. The total number of pages, total number of photographs and word counts separately for abstract and for the text (excluding the references and abstract)
8. Source(s) of support in the form of grants, equipment, drugs or all of these

ABSTRACT (OR INTRODUCTION) AND KEYWORDS

The second page should carry the full title of the manuscript and an abstract (of no more than 150 words for case reports, brief reports and 250 words for original articles). The structured abstract should consist of no more than 250 words and the following four paragraphs:

- **Background:** Describes the problem being addressed
- **Methods:** Describes how the study was performed
- **Results:** Describes the primary results
- **Conclusions:** Reports what authors have concluded from these results and notes their clinical implications.

TEXT

Introduction

The introduction contains a concise review of the subject area and the rationale for the study. More detailed comparisons to previous work and conclusions of the study should appear in the discussion section.

Materials and Methods

This section lists the methods used in the study in sufficient detail so that other investigators would be able to reproduce the research. When established methods are used, the authors' need only refer to previously published reports; however, the authors should provide brief descriptions of methods that are not well known or that have been modified. Identify all drugs and chemicals used, including both generic and, if necessary, proprietary names and doses. The population for research involving humans should be clearly defined and enrolment dates provided.

Results

Results should be presented in a logical sequence with reference to tables, figures and illustrations as appropriate.

Discussion

New and possible important findings of the study should be emphasised as well as any conclusions that can be drawn. The discussion should compare the present data to previous findings. Limitations of the experimental methods should be indicated, as should implications for future research. New hypotheses and clinical recommendations are appropriate and should be clearly identified. Recommendations, particularly clinical ones, may be included when appropriate.

ACKNOWLEDGMENTS AND CONFLICTS OF INTEREST

Acknowledgments

At the end of the discussion, acknowledgments may be made to individuals who contributed to the research or the manuscript preparation at a level that did not qualify for authorship. This may include technical help or participation in a clinical study. Authors are responsible for obtaining written permission from persons listed by name. Acknowledgments must also include a statement that includes the source of any funding for the study and defines the commercial relationships of each author.

Conflicts of Interest

In the interest of transparency and to allow readers to form their own assessment of potential biases that may have influenced the results of research studies, the journal requires that all authors declare potential competing interests relating to papers accepted for publication. Conflicts of interest is defined as those influences that may potentially undermine the objectivity or integrity of the research, or create a perceived conflict of interest.

Authors are required to submit: (1) A statement in the manuscript, following acknowledgments, that includes the source of any funding for the study, and defines the commercial relationships of each author. If an author has no commercial relationships to declare, a statement to that effect should be included. This statement should include financial relationships that may pose a conflict of interest or potential conflict of interest. These may include financial support for research (salaries, equipment, supplies, travel reimbursement); employment or anticipated employment by any organization that may gain or lose financially through publication of the paper; and personal financial interests, such as shares in or ownership of companies affected by publication of the research, patents or patent applications whose value may be affected by this publication, and consulting fees or royalties from organizations which may profit or lose as a result of publication. (2) A conflict of interest and financial disclosure form for each author. Conflict of interest information will not be used as a basis for suitability of the manuscript for publication.

REFERENCES

References should be numbered consecutively in the order in which they appear in the text. A journal, magazine or newspaper article should be given only one number; a book should be given a different number each time it is mentioned, if different page numbers are cited. All references are identified, whether they appear in the text, tables or legends, by Arabic numbers in superscript. The use of abstracts as references is strongly discouraged. Manuscripts accepted for publication may be cited. Material submitted, but not yet accepted, should be cited in text as 'unpublished observations'. Written and oral personal communications may be referred to in text but not cited as references. Please provide the date of the communication and indicate whether it was in a written or oral form. In addition, please identify the individual and his/her affiliation. Authors should obtain written permission and confirmation of accuracy from the source of a personal communication. Presented papers, unless they are subsequently published in a proceedings or peer-reviewed journal, may not be cited as references. In addition, Wikipedia.org may not be cited as a reference. For most manuscripts, authors should limit references to materials published in peer-reviewed professional journals. In addition, authors should verify all references against the original documents. References should be typed double-spaced.

TABLES

Tables should be numbered consecutively in Arabic numbers in the order of their appearance in the text. A brief descriptive title should be supplied for each. Explanations, including abbreviations, should be listed as footnotes not in the heading. Every column should have a heading. Statistical measures of variations, such as standard deviation or standard error of the mean, should be included as appropriate in the footnotes. Do not use internal horizontal or vertical rules.

FIGURE LEGENDS

Legends should be typed double-spaced with Arabic numbers corresponding to the figure. When arrows, symbols, numbers or letters are used, explain each clearly in the legend; also explain internal scale, original magnification and method of staining as appropriate. Panel labels should be in capital letters. Legends should not appear on the same page as the actual figures.

FIGURES

Digital files must be submitted for all figures. Submit one file per figure. Human subjects must not be identifiable in photographs, unless written permission is obtained and accompanies the photograph. Lettering, arrows or other identifying symbols should be large enough to permit reduction and must be embedded in the figure file. Figure file names must include the figure number. Details of programs used to prepare digital images must be given to facilitate the use of the electronic image. Use solid or shaded tones for graphs and charts. Patterns other than diagonal lines may not reproduce well.

UNITS OF MEASUREMENT

Measurements of length, height, weight and volume should be reported in metric units or their decimal multiples. All hematologic and clinical chemistry measurements should be reported in the metric system in terms of the International System of Units (SI).

STATISTICS

Statistical methods should be described such that a knowledgeable reader with access to the original data could verify the results. Wherever possible, results should be quantified and appropriate indicators of measurement error or uncertainty given. Sole reliance on statistical hypothesis testing or normalization of data should be avoided. Data in as close to the original form as reasonable should be presented. Details about eligibility criteria for subjects, randomization and methods for blinding of observations, treatment complications and numbers of observations should be included. Losses to observations, such as dropouts from a clinical trial, should be indicated. General-use computer programs should be listed. Statistical terms, abbreviations and symbols, should be defined. Detailed statistical, analytical procedures can be included as an appendix to the paper, if appropriate.

FOOTNOTES

Footnotes should be used only to identify author affiliation to explain symbols in tables and illustrations and to identify manufacturers of equipment, medications, materials and devices. Use the following symbols in the sequence shown: *, †, ‡, §, k, #, **, ††, etc.

IDENTIFICATION OF PRODUCTS

Use of brand names within the title or text is not acceptable, unless essential when the paper is comparing two or more products. When identification of a product is needed or helpful to explain the procedure or trial being discussed, a generic term should be used and the brand name, manufacturer and location (city/state/country) cited as a footnote.

Journal of Contemporary Dentistry

Copyright Ownership and Legal Rights Statement

CONDITIONS FOR SUBMISSION

You warrant that the work/contribution is your original research material and has not been published before and should not be under consideration of publication elsewhere except for previous publication in form of an abstract or as part of published literature (review or thesis) as may be included with the written permission of the copyright owners. You further warrant that the work/contribution (i) is not subject to any prior claim, encumbrance or agreement, (ii) will include appropriate warnings of harmful instructions, formulas and procedures, and (iii) will not contain any material that violates any copyright, personal proprietary or other right. This exclusive grant of rights under this Agreement means that you may not delegate, assign, sub-contract or license the work/contribution in whole or in part to third parties without the prior written consent of the Publisher.

If your work/contribution contains extracts or material from other copyright works, you will obtain at your own expense before a paper can be considered for publication along with written permission, which shall be forwarded to the Publisher on delivery of the work/contribution from each copyright holder to use and reprint such material in all versions, forms and media now or hereafter known, including all existing and future copyright and any renewals and extensions thereof anywhere in the world. Furthermore, you will identify such material (if any) in the work/contribution and provide full and appropriate acknowledgement of its source. If such permissions are not obtained in a timely manner, you will provide substitute material, revise the work/contribution accordingly and obtain the requisite substitute permissions, if necessary. If relevant, you will obtain medical patient releases from patients if information about them or illustrations of them are used in the work/contribution.

COPYRIGHT TRANSFER

Once the corresponding author has signed the Copyright Transfer form, Jaypee Brothers would accept no change in authorship or in the order of the authors listed in the work/contribution. Also by signing the concerned form, the author reassigns the rights of copublishing, or translation, including the digital rights, if considered necessary in future to the publisher. In the advent of occurrence any dispute, the matter would be resolved within the jurisdiction of New Delhi court.

LEGAL OBLIGATIONS

While all care has been taken to provide accurate and correct information in accordance with the date of publication, neither the authors, editors nor publisher takes any legal responsibility for any unintentional omission or error. The publisher makes no expressed or implied warranty with respect to the information contained herein. The published material cannot be photocopied for the following purposes: general distribution, promotion, new works or resale. If this is required, specific written permission requires to be obtained from the publisher. Exclusive rights to reproduce and distribute the articles in this journal have been protected by copyright. This also covers the rights to reproduce or distribute the article as well as the translation rights. No material published in this journal can be reproduced in digital format or stored in form of electronic databases, video disks, etc without the prior permission from the publisher.

1. COPYRIGHT TRANSFER FORM

I have read the above mentioned details related to copyright of the work/contribution submitted and I _____, the author of

_____ certify that I willingly assign the copyright of my work/contribution _____ to the publisher M/S Jaypee Brothers Medical Publishers (P) Ltd., who will have the exclusive right of producing (in print or digital format) the complete work or any portion of it.

I hereby certify that the work which I am submitting to the publisher is my own and does not contain any matter which in anyway is infringement of the copyright law.

Name: _____

Date signed: _____

2. FINANCIAL DISCLOSURE

This is to certify that I _____, the author of

_____ certify that I do not have any commercial association or financial interest in the publication of this work/contribution.

Name: _____

Date signed: _____

3. CONFLICT OF INTEREST

This is to certify that I _____, the author of

_____ certify that I do not have any commercial association or financial interest in the publication of this work/contribution.

Name: _____

Date signed: _____