

**Information of Director of Training Centre**  
**It shall be verified by the Head of the concerned Training Center**

Sr. No.	Particular	Information to be filled												
1.	Name of Director	: Dr. Srivalli Natarajan												
2.	Date of Birth	: 08/03/1970												
3.	Address	: 10, 504, Dhiraj Dreams, Co-Op-Hsg, Soc, LBS Marg Bhandup												
4.	Tel. No./ Mob. No.	: 9769088803												
5.	e-mail id	: srivalli.shrikanth@gmail.com												
6.	Nationality	: Indian												
7.	Qualification in details : (attach documentary proof)	: MDS, Oral & Maxillofacial Surgery												
8.	Teaching Experience / Health Sciences: Profession Experience (Attached document proof with signature of Head of the Institute. Also it is mandatory to attach self-attested Photocopy of the Experience Certificate of each Mentor in the Subject of concerned Fellowship/Certificate Course)	: 25years 3dys.												
9.	Present Appointment	: Dean, Professor and HOD												
10.	Publications (List & Proof)	<table border="1"> <tbody> <tr> <td>1.</td> <td>Vichare SN, Natarajan S, Baviskar PS, Ahuja SA, Vathare PP. Glandular odontogenic cyst mimickers: A review and report of two cases. Journal of Mahatma Gandhi Institute of Medical Sciences. 2021 Jul 1;26(2):124.</td> </tr> <tr> <td>2.</td> <td>Oswal Y, Natarajan S, Deshpande G, Patil N. Comparative evaluation of Palatal length, speech outcome and surgical complications with use of von langenkback and bardach 2 flap technique for the repair of cleft palate: A Prospective Randomized Study. FACE 2021;1-11.</td> </tr> <tr> <td>3.</td> <td>Baviskar P, Natarajan S. Use of custom fabricated surgical jig to improve surgical outcomes in open reduction internal fixation of unilateral orbitalfractures: A prospective clinical study. Saudi Journal of Ophthalmology 2021; Vol XX Issue XX:Page XX</td> </tr> <tr> <td>4.</td> <td>Sabnis AS, Natarajan S. Cytogenic evaluation of Orofacial clefts. Natl J Clin Anat2021;10:199-204.</td> </tr> <tr> <td>5.</td> <td>Ujwala M, Shweta M, Navdeep K, Haripriya K, Srivalli S. Need of the Hour : Early and Rapid Diagnosis of Black Fungus (Mucormycosis) Maiming the Covid Patients in India!!!International Journal of Scientific Research and Reviews. 2021, 10(2), 98-104</td> </tr> <tr> <td>6.</td> <td>Chapter 47 - Design, Additive Manufacturing and Application of Patient-Customized Orbital Implants Smart Innovation, Systems and Technologies Volume 223, ISSN 2190-3018 ISSN 2190-3026 (electronic), Smart Innovation, Systems and Technologies ISBN 978-981-16-0083-8 ISBN 978-981-16-0084-5 (eBook), <a href="https://doi.org/10.1007/978-981-16-0084-5">https://doi.org/10.1007/978-981-16-0084-5</a> Authors: Samrat Sagar, SrivalliNatarajan, Suraj Naik, Bhanupratap Gaur, M. Suryawanshi Chetana, Shehbaz Ali Syed, Burhan Khambati, Rupesh Ghyar, and Ravi Bhallamudi</td> </tr> </tbody> </table>	1.	Vichare SN, Natarajan S, Baviskar PS, Ahuja SA, Vathare PP. Glandular odontogenic cyst mimickers: A review and report of two cases. Journal of Mahatma Gandhi Institute of Medical Sciences. 2021 Jul 1;26(2):124.	2.	Oswal Y, Natarajan S, Deshpande G, Patil N. Comparative evaluation of Palatal length, speech outcome and surgical complications with use of von langenkback and bardach 2 flap technique for the repair of cleft palate: A Prospective Randomized Study. FACE 2021;1-11.	3.	Baviskar P, Natarajan S. Use of custom fabricated surgical jig to improve surgical outcomes in open reduction internal fixation of unilateral orbitalfractures: A prospective clinical study. Saudi Journal of Ophthalmology 2021; Vol XX Issue XX:Page XX	4.	Sabnis AS, Natarajan S. Cytogenic evaluation of Orofacial clefts. Natl J Clin Anat2021;10:199-204.	5.	Ujwala M, Shweta M, Navdeep K, Haripriya K, Srivalli S. Need of the Hour : Early and Rapid Diagnosis of Black Fungus (Mucormycosis) Maiming the Covid Patients in India!!!International Journal of Scientific Research and Reviews. 2021, 10(2), 98-104	6.	Chapter 47 - Design, Additive Manufacturing and Application of Patient-Customized Orbital Implants Smart Innovation, Systems and Technologies Volume 223, ISSN 2190-3018 ISSN 2190-3026 (electronic), Smart Innovation, Systems and Technologies ISBN 978-981-16-0083-8 ISBN 978-981-16-0084-5 (eBook), <a href="https://doi.org/10.1007/978-981-16-0084-5">https://doi.org/10.1007/978-981-16-0084-5</a> Authors: Samrat Sagar, SrivalliNatarajan, Suraj Naik, Bhanupratap Gaur, M. Suryawanshi Chetana, Shehbaz Ali Syed, Burhan Khambati, Rupesh Ghyar, and Ravi Bhallamudi
1.	Vichare SN, Natarajan S, Baviskar PS, Ahuja SA, Vathare PP. Glandular odontogenic cyst mimickers: A review and report of two cases. Journal of Mahatma Gandhi Institute of Medical Sciences. 2021 Jul 1;26(2):124.													
2.	Oswal Y, Natarajan S, Deshpande G, Patil N. Comparative evaluation of Palatal length, speech outcome and surgical complications with use of von langenkback and bardach 2 flap technique for the repair of cleft palate: A Prospective Randomized Study. FACE 2021;1-11.													
3.	Baviskar P, Natarajan S. Use of custom fabricated surgical jig to improve surgical outcomes in open reduction internal fixation of unilateral orbitalfractures: A prospective clinical study. Saudi Journal of Ophthalmology 2021; Vol XX Issue XX:Page XX													
4.	Sabnis AS, Natarajan S. Cytogenic evaluation of Orofacial clefts. Natl J Clin Anat2021;10:199-204.													
5.	Ujwala M, Shweta M, Navdeep K, Haripriya K, Srivalli S. Need of the Hour : Early and Rapid Diagnosis of Black Fungus (Mucormycosis) Maiming the Covid Patients in India!!!International Journal of Scientific Research and Reviews. 2021, 10(2), 98-104													
6.	Chapter 47 - Design, Additive Manufacturing and Application of Patient-Customized Orbital Implants Smart Innovation, Systems and Technologies Volume 223, ISSN 2190-3018 ISSN 2190-3026 (electronic), Smart Innovation, Systems and Technologies ISBN 978-981-16-0083-8 ISBN 978-981-16-0084-5 (eBook), <a href="https://doi.org/10.1007/978-981-16-0084-5">https://doi.org/10.1007/978-981-16-0084-5</a> Authors: Samrat Sagar, SrivalliNatarajan, Suraj Naik, Bhanupratap Gaur, M. Suryawanshi Chetana, Shehbaz Ali Syed, Burhan Khambati, Rupesh Ghyar, and Ravi Bhallamudi													

10. Publications (List & Proof)

7.	Chapter 48 - Guidelines to Design Custom 3D Printed Jig for Orthopaedic Surgery Smart Innovation, Systems and Technologies Volume 223, ISSN 2190-3018 ISSN 2190-3026 (electronic), Smart Innovation, Systems and Technologies ISBN 978-981-16-0083-8 ISBN 978-981-16-0084-5 (eBook), <a href="https://doi.org/10.1007/978-981-16-0084-5">https://doi.org/10.1007/978-981-16-0084-5</a> Authors: Shehbaz Ali Syed, Bhanupratap Gaur, Samrat Sagar, M. Suryawanshi Chetana, Suraj Naik, Burhan Khambati, Srivalli Natrajan, Rupesh Ghyar, and Ravi Bhallamudi
8.	Natarajan S, Baviskar PS, Gandevivala A, Gupta H, Vichare SN. Traumatic Optic Neuropathy in Orbital Wall Fractures-Diagnostic Parameters and Treatment Outcomes: A Prospective Observational Study. Journal of Stomatology, Oral and Maxillofacial Surgery. 2021 Jun 23.
9.	Dr. Sunil Sidana, Dr. Prachi Goyal, Dr. Srivalli Natarajan, Dr. Shilpa Patel, Dr. Niharika Swain, Dr. Padmakar Baviskar. Is there a correlation between radiographic presentation of multilocularity and aggressive histology of unicystic ameloblastomas.- Report of two cases and Review of literature. Journal of Asian Journal of Dental Sciences. 2021; 4(2); 39-48
10.	Baviskar PS, Ahuja SA, Natarajan S, Bagchi PR. Tetanus of suspected dental causality. Journal of stomatology, oral and maxillofacial surgery. 2021 Feb 1;122(1):115-8.
11.	Sinha A, Natarajan S. Comparative Evaluation of Clinical and Radiological Outcomes of Retromandibular Transparotid and Transoral Endoscopic-Assisted Approach for Surgical Management of Mandibular Subcondylar Fractures. Craniomaxillofacial Trauma & Reconstruction. 2021 Jun;14(2):90-9.
12.	Usha Asnani, Srivalli Natarajan, Nitesh Patkar, Suraj Ahuja, Abhishek Datta, Imran Khalid. Evaluation of incidence of neurosensory deficits following removal of impacted mandibular third molar : A Prospective Clinical Study of 100 cases. INT J Oral Health Med Res, March – April 2020.
13.	Post Graduate Diploma in Clinical Research- James Lind University
14.	Sushrut Vaidya, Srivalli Natarajan, Usha Asnani, Nitesh Patkar, Adil Gandevivala. A Rare Occurrence of mucous retention cyst in midcheek region: A Case Report. Int Arch Oral Maxillofac Surg 2019.
15.	Sidana S, Natrajan S, Vathare PP, Kadam S, Shah SB. Basal Cell Carcinoma in Medial Canthal Region. J Contemp Dent 2019; 9 (3):141-143.
16.	Borescope: A frugal tool for capturing cleft palatal surgeries Journal of Plastic, Reconstructive & Aesthetic Surgery Dr. Suraj Arjun Ahuja, Dr. Gaurav Deshpande, Dr. Abhishek Dutta, Dr. Srivalli Natarajan, Dr. Usha Asnani, Dr. Imran Khalid Volume 72, Issue 9, September 2019, Pages 1576-1606
17.	Deshmukh M, Vaidya S, Deshpande G, Galinde J, Natarajan S. Comparative evaluation of esthetic outcomes in unilateral cleft lip repair between the Mohler and Fisher repair techniques: a prospective, randomized, observer-blind study. Journal of Oral and Maxillofacial Surgery. 2019 Jan 1;77(1):182-e1.
18.	Srivalli Natarajan, Taher Abbas Mistry, Usha Asnani – Evaluation of the Prevalence of Comorbidities in Patients Reporting for Dentoalveolar Surgeries – Original Research - Indian Journal of Dental Research –Vol 30, Issue –6; 860-863.

- |     |  |
|-----|--|
| 19. | Taher M, Srivalli N, Yusuf M. Comparative Evaluation of Clinical Outcomes of Laser Skin Resurfacing Using an Ultra-Pulse Carbon Dioxide Laser and Manual Dermabrasion Using a Medium-Grit Drywall Sand Screen for Scar Revision in Adults: A Split-Scar Prospective Study. <i>Journal of Oral and Maxillofacial Surgery</i> . 2019 Feb 1;77(2):411-e1. |
| 20. | Dutta A, Ahuja S, Asnani U, Natarajan S, Vaidya S, Gandevivala A. Looking back at zygomatic fractures: what, when and how for better treatment planning - a retrospective analysis. <i>Br J Pharma Med Res</i> 2018,1(6):1404-1413.  |
| 21. | Sneha Kadam, Sushrut Vaidya, Jyotsna Galinde, SrivalliNatarajan. Clinical outcome of rapid absorbable irradiated polyglactin 910 suture versus non-absorbable ethilon suture in closure of the skin wounds of head and neck region –a comparative study. <i>.Int J Sc Research Volume-7   Issue-4   April-2018(PUBMED)</i>                             |
| 22. | Dinesh Shah, Srivalli Natarajan – Corelation between incidence and spectrum of ophthalmic injuries patterns of craniofacial fractures involving orbital walls a prospective study – <i>International Journal of Scientific Research – Vol - 7, Issue3 March – 2018 (PUBMED)</i>  |
| 23. | Himika Gupta , Srivalli Natarajan, Sushrut Vaidya, Shipra Gupta, Dinesh Shah Raj Merchant Shrikant Deshpande – Traumatic eye ball luxation: A stepwise approach to globe salvage - <i>Saudi Journal Of Ophthalmology .2017 31,260-265 (PUBMED)</i>   |
| 24. | Ahuja SA, Natarajan S , Galinde J, Asnani U: Management of parotid sialocele using botulinum toxin type –A Novel conservative approach <i>Annals of dental speciality Vol5; issue 3 2017</i>   |
| 25. | Sushrut Vaidya, SrivalliNatarajan, Suraj Arjun Ahuja, Gas gangrene in the Neck caused by an odontogenic, Infection - A case report. <i>Journal of surgery 2017, J129 - volmee 2017 ISSUE 06 (PUBMED)</i>   |
| 26. | Gauri kokane ,Srivalli Natarajan ,Demonstration & characterization of stem cells in pulp tissue of human third molar teeth: A ex-vivo study <i>International Journal of scientific research: Vol 6 / issue -12 / dec 2017(PUBMED)</i>  |
| 27. | Srivalli Natarajan , Yusuf A Mistry, Taher Mistry, Shailesh Kokal - Oral Myiasis – A Paoper’s Affection : Case Reports and A Review of 62 Cases – <i>Journal of Contemporary Dentistry , January – April 2017:7(1) 62-70</i>   |
| 28. | Yusuf Abbas Mistry, Srivalli S. Natarajan , Suraj A. Ahuja - A Comparative Evaluation of Laser Tissue Welding and Laser – Tissue Soldering for Mucosal and Vascular Repair: An In Vitro Study – Original Article – <i>In Vitro Study – (Original Article) – Annals of Maxillofacial Surgery – Vol – 8, Issue – 01 - 2017(PUBMED)</i>                   |
| 29. | Sushrut Vaidya, SrivalliNatarajan, Sneha kadam Primary Non – Hodgkin’s Lymphoma involving Parotid Galand : A Rare Entity. . <i>J Contemp Dent Jan-April2017; 7(1):1-5.</i>   |
| 30. | Natarajan S, Ahuja S, Asnani U – Incidence of Airway Compromise in Patients with Head, Face and Nweck Injuries – An Observational Study – Case Report - <i>Intenational Journal of Oral Health and Medical Research - 2016:3:1-5.</i>  |
| 31. | Natarajan S, Khalid I. Glandular odontogenic cyst mimicking a radicular cyst: a case series. <i>International Journal of Medical and Dental Case Reports</i> . 2016;3(1):1-4.  |
| 32. | Jatinder Nath Khanna, Srivalli Natarajan, Jyotsna Galinde-RhinocerebralMucormycosis – An emerging threat – <i>Journal of Oral and Maxillofacial Surgery, Medicine, and Pathology 27 (2015) 550-557(PUBMED)</i>   |

10	Publications (List & Proof)	:	33.	Abhishek Mistry, Richard Pereira, Vineet Kini, Ashvini Padhye, L.S. Poonja, Srivalli N – Management of on Unresponsive Periodontal Lesion in an Endodontic Involved Tooth Complicated by Actinomyces Species.- Journal of Contemporary Dentistry. September-December 2014;4(3):167-172.
			34.	J. N. Khanna, Srivalli Natrajan, J. S. Galinde. Skull Base Tumors: A Kaleidoscope of Challenge J Neurol Surg Rep 2014; 75(01): e11-e21. (PUBMED)
			35.	Radhika Ramaswami, Jyotsna Galinde, NSrivalli, Sunil Sidana – Keratocystic Odontogenic Tumor - Journal of Contemporary Dentistry. May-August 2013;3(1):87-91.
			36.	Sushrut Vaidya, Sunil Sidana, Jyotsna Galinde, Srivalli N. – Osteochondroma of the Mandibular Condyle – Journal of Contemporary Dentistry. Sep-Dec 2012;2(3):106-108
			37.	Srivalli Natrajan, Jyotsna S Galinde, Usha Asnani, Sunil Sidana, Radhika Ramaswami – Facial Dog Bite Injury – Journal of Contemporary Dentistry May-August 2012;2(2): 34-38.
			38.	Usha Asnani, Jyotsna S. Galinde, Srivalli Natrajan, Mahesh Sonar. – Florid Cemento-osseous dysplasia.- Journal of Contemporary Dentistry. April 2012; 2(1):53-56
			39.	Sushrut Vaidya, Srivalli Natrajan, Imran Khalid, Alok Bhardwaj. – Calculi in Parotid Duct: A rare case report. – Indian J Stomatol 2012; 3(1):62-65
			40.	Sushrut Vaidya, Srivalli Natrajan, Jyotsna S. Galinde, Alok Bhardwaj. – Juxtacortical osteosarcoma of Mandible.- Annals of Maxillofacial Surgery. 2011;1(2):172-175(PUBMED)
			41.	Usha Asnani, Smita Sonavane, Srivalli Natrajan, Fawaz Baig. – Panfacial Trauma.- International Journal of Dental Clinics. April-June 2010; 2(2):35-38(PUBMED)
			42.	J. S. Galinde, Srivalli Natrajan. – Fibro-osseous lesions of jaws.- International Journal of Oral & Maxillofacial Surgery. May 2009; 38(5):483(PUBMED)
12	Post Graduate Teaching experience (Attach documentary evidence)	:	13 years. 9 months	
13	Any other relevant information	:	-	

Date :- 20/05/2022  
For the use of affiliated Training Centre:

*S. Srivalli*  
Dr. Srivalli Natarajan  
Name & Sign. of Director

I have verified the eligibility of the above Director as per the criteria of eligibility prescribed by the University vide clause no.7 of the University Direction No. 05/2017 (Amended).

*S. Srivalli*  
Sign & Stamp  
Head of the Department  
Date: 20/05/2022

*S. Srivalli*  
Sign & Stamp  
Director of Training Centre  
Date: 20/05/2022





சென்னைப் பல்கலைக் கழகப் பேரவை.....1991.....ஆம் ஆண்டு  
 அக்டோபர்.....மாதம் நடந்த பற்கள் சார் அறுவையியல் இளையர் தேரலில்  
 ந. ஸ்ரீ வள்ளி.....என்பவர் தேர்ச்சி பெற்றார் என்று  
 தக்க தேர்வாளர்கள் சான்றளித்தபடி பற்கள் சார் அறுவையியலில் இளையர்  
 பட்டத்தை அவருக்குப் பல்கலைக் கழக இலச்சினையுடன் வழங்குகிறது.

The Senate of the UNIVERSITY OF MADRAS hereby makes  
 known that N. Srivalli..... has been admitted to  
 the Degree of Bachelor of Dental Surgery, she having been  
 certified by duly appointed Examiners to be qualified to receive the same at the  
 Examination held in October 1991.....

Given under the seal of the University.

சேப்பாக்கம், Choppak,  
 சென்னை, Madras,  
 நாள்: Dated 26-3-1993...

*[Signature]*  
 பதிவாளர்,  
 Registrar.

*[Signature]*  
 Dean  
 M.G.M. Dental College Hospital  
 Kanchi, Nari Medical College  
 துணை வேந்தர்,  
 Vice-Chancellor.



The Tamil Nadu Dr. M.G.R. Medical University  
MADRAS

FACULTY OF DENTISTRY

The Governing Council of THE TAMIL NADU  
Dr. M. G. R. MEDICAL UNIVERSITY hereby makes known that

SRIVALLI N.

has been admitted to the Degree of MASTER OF DENTAL SURGERY  
in the Branch of ORAL AND MAXILLOFACIAL SURGERY he/she having been certified  
by duly appointed Examiners to have qualified to receive the  
same at the Examination held in SEPTEMBER 1996.



Given under the Seal of the University.

Madras  
Date 21.3.1997.

Date of issue 14 AUG 1997

*Registrar*  
Registrar  
M.G.R. Medical College and Hospital,  
Kamotho, Navi Mumbai 410 209.

*Vice-Chancellor*  
Vice-Chancellor  
Dr. (Major) D. RAJA,  
M.S.,(ORTHO)D,ORTHO.,FIAS, FIMSA



महाराष्ट्र आरोग्य विज्ञान विद्यापीठ  
MAHARASHTRA UNIVERSITY OF HEALTH SCIENCES

वणी रोड, म्हस्रुळ, नाशिक - ४२२ ००४  
Vani Road, Mhasrul, Nashik - 422 004

Vidya Thakare

M. Sc., D. Phar

Dy. Registrar

Phone: 0253-2539199 / EPABX: 0253-2539100 - 300 / Fax: 0253-2539200

E-mail: pgacademic@muhsnashik.com / Web: www.muhsnashik.com

Phone : 0253- 2539199

No. MUHS/E-2/PG/PGTRC/ 732 /2010

Date: 22 /04/2010

To,  
The Dean / Principal,  
Mahatma Gandhi Mission's Dental College & Hospital,  
Juncation of NH-4 and sion Panvel Expressway,  
Sector - 18, Kamothe,  
Navi Mumbai - 410209.

Sub: - Recognition as Post-Graduate Teacher...

Ref.: - University letter no. MUHS/E-2/PG/PGTRC/1154/2009 dtd. 31/07/09

Sir / Madam,

With reference to the above cited subject, I am to directed to inform you that in view of the norms prescribed as per provision under the section 29(2)(I) of the MUHS Act, 1998 Hon'ble Vice-Chancellor is pleased to grant recognition as Post-Graduate Teacher to the following teacher(s) of your College **subject to the terms and conditions of appointment order** for imparting instructions to the Post Graduate Degree in the subject mentioned against his name.

Sr. No.	Name of the Teacher	Subject	Status of PG Recognition
01	Dr. Shrivalli Natarajan	Oral & Maxillofacial Surgery	w.e.f. 21/01/2010

Kindly note that the recognition given by the University is valid till the above said teacher(s) is in services of the Private Dental College or attains the age of superannuation whichever is earlier. Recognition granted is subject to approval of this University to appointment(s). You are requested to handover the copy of letter to the concerned teacher(s).

Dr. Shrivalli Natarajan  
4/5/10

Dr. Shrivalli Natarajan & Hospital  
KAMOTHE

Inward No. 216/10  
Date 4/5/10

Yours faithfully,

*Vidya*

Dy. Registrar  
I/C Academic Section (PG)

- Copy to : 1) The Controller of Examinations, MUHS, Nashik  
2) The Synopsis Section, MUHS, Nashik

*[Signature]*

Dean

Note: In case, if it is found at later stage that information furnished in Post Graduate Recognition form by any teacher is incorrect, PG Recognition / UG approval granted by the University will stand cancelled.

# Comparative Evaluation of Clinical and Radiological Outcomes of Retromandibular Transparotid and Transoral Endoscopic-Assisted Approach for Surgical Management of Mandibular Subcondylar Fractures

Craniomaxillofacial Trauma & Reconstruction  
1-10

© The Author(s) 2020  
Article reuse guidelines:  
sagepub.com/journals-permissions  
DOI: 10.1177/1943387520949099  
journals.sagepub.com/home/cmt



Ajit Sinha, MDS<sup>1</sup>, and Srivalli Natarajan, MDS<sup>1</sup>

## Abstract

**Study Design:** A prospective randomized comparative study was conducted to evaluate the clinical and radiological outcomes of the retromandibular transparotid (RMT) approach with endoscopic-assisted transoral (ENDO) approach used for open reduction and internal fixation (ORIF) of adult mandibular subcondylar fractures.

**Objectives:** To evaluate and compare the primary functional outcome using the Helkimo's dysfunction index, the surgical ease, the incidence of facial nerve weakness, the cosmetic outcomes and the number of complications following ORIF of mandibular subcondylar fractures using the RMT and ENDO approaches.

**Methods:** In this prospective study, 20 patients with unilateral/bilateral subcondylar fractures requiring ORIF were recruited between 2017 and 2018. Patients were randomly divided into RMT and ENDO group, 10 patients in each. Clinical and radiological assessment was done preoperatively and in postoperative period it was done at different intervals over the period of 6 months. The intraoperative parameter time taken during surgery was correlated for association with the time elapsed since day of trauma and with the fracture severity. Similarly, the presence of multiple fractures of the mandible and postoperative occlusion were evaluated for the association.

**Results:** Comparable functional results were noted in both groups without any statistical significance. ORIF in ENDO group proved to be more time-consuming. For the RMT group, visible scars were rated best or close to best at the end of 6 months but a greater number of facial nerve injuries were reported in the RMT group.

**Conclusions:** Superiority of one approach over others cannot be established since the outcomes were not statistically different. However, the ENDO approach appears to be safer. Therefore, there is a need for the development of innovative armamentarium which would improve the dexterity and ease of the surgeon and hence the total time taken for this minimally invasive approach for the management of subcondylar fracture.

## Keywords

mandibular subcondylar fractures, retromandibular transparotid approach, endoscopic-assisted transoral approach

## Introduction

In the field of maxillofacial trauma, the mandibular condylar fractures are the most controversial regarding the diagnosis and treatment as reflected in the wide variety of opinions and proposed treatment modalities discussed in the literature.<sup>1-3</sup> The treatment of condylar fractures should target a maximum reduction of morbidity, post-operative complications, and esthetic and/or functional impairment.<sup>4</sup> After several years of debate, the

<sup>1</sup>Department of Oral and Maxillofacial Surgery, MGM Dental College and Hospital, Navi Mumbai, Maharashtra, India

### Corresponding Author:

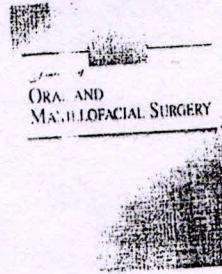
Ajit Sinha, MDS, Department of Oral and Maxillofacial Surgery, MGM Dental College and Hospital, Junction of NH4 and Sion-Panvel Expressway, Sector 1, Kamothe, Navi Mumbai 410209, Maharashtra, India.  
Email: dr.ajitsinha03@gmail.com

Dean

MGM Dental College and Hospital,  
Kamothe, Navi Mumbai, Maharashtra, India



Accepted Manuscript



"Comparative Evaluation of Aesthetic Outcomes in Unilateral Cleft Lip Repair Between Mohler's And Fisher's Repair Techniques – A Prospective, Randomised Observer Blind Study."

Mazin Deshmukh, MDS, Sushrut Vaidya, MDS, Gaurav Deshpande, MDS, Jyotsna Galinde, MDS, Srivalli Natarajan, MDS

PII: S0278-2391(18)30994-7

DOI: 10.1016/j.joms.2018.08.029

Reference: YJOMS 58439

To appear in: *Journal of Oral and Maxillofacial Surgery*

Received Date: 10 April 2018

Revised Date: 25 August 2018

Accepted Date: 27 August 2018

Please cite this article as: Deshmukh M, Vaidya S, Deshpande G, Galinde J, Natarajan S, "Comparative Evaluation of Aesthetic Outcomes in Unilateral Cleft Lip Repair Between Mohler's And Fisher's Repair Techniques – A Prospective, Randomised Observer Blind Study.", *Journal of Oral and Maxillofacial Surgery* (2018), doi: 10.1016/j.joms.2018.08.029.

This is a PDF file of an unedited manuscript that has been accepted for publication. As a service to our customers we are providing this early version of the manuscript. The manuscript will undergo copyediting, typesetting, and review of the resulting proof before it is published in its final form. Please note that during the production process errors may be discovered which could affect the content, and all legal disclaimers that apply to the journal pertain.

A handwritten signature in black ink, appearing to be 'SM', is located above the Dean's name.

Dean

Faculty of Dental College of Maharashtra,  
Kamotia, Navi Mumbai - 401 304.

A handwritten signature in black ink, appearing to be 'SM', is located above the author's name.

M.C.M. Deshmukh, M.D.S., M.B.B.S.,  
Kamotia, Navi Mumbai - 401 304.

# Cytogenetic Evaluation of Orofacial Clefts

Anjali Satyen Sabnis, Srivalli Natrajan<sup>1</sup>

Professor and Head, Department of Anatomy, MGM Medical College and Hospital, <sup>1</sup>Professor and Head, Department of Oral and Maxillofacial Surgery, MGM Dental College, Navi Mumbai, Maharashtra, India

## Abstract

**Background:** Orofacial cleft (OFC) is one of the common congenital anomalies of the face which includes cleft lip and or cleft palate that causes abnormal appearance of the face. It leads to difficulty in speech and feeding, especially in new-borns. Genetic and nongenetic factors may lead to OFCs. An association of OFC to genetic cause was assessed in the study. **Methodology:** Conventional karyotyping was done in 133 patients of all the age groups with OFCs (syndromic and nonsyndromic) to find out chromosomal aberrations (CAs) in OFCs, Department of Oral and Maxillofacial Surgery, MGM Dental College, Navi Mumbai directed patients to cytogenetic laboratory. Project was started after taking consent and ascent from the patient and institutional ethical approval. **Results:** The incidence of CAs is 2.2%, and polymorphic variations are 3.7%. Out of 133 patients 47, XXY was seen in one case and trisomy 21 was seen in two cases, polymorphic variations like pericentric inversion in chromosome 9, 16qh+ and 22 pstk+ were observed in one case each and 9qh+ was seen in two cases. **Conclusion:** The incidence of genetic involvement in terms of CAs and polymorphic variations to OFC is low. The application of molecular technique in patients with OFC will help to find out genetic involvement. Genetic counseling and precise prenatal diagnosis will prevent the incidence of OFC.

**Keywords:** Cleft lip, cleft palate, karyotyping, orofacial cleft

## INTRODUCTION

Orofacial clefts (OFCs) are highly prevalent abnormalities of the lip and or palate caused because of failure of partial or complete fusion of maxillary and mandibular process during the development of the face. Unilateral or bilateral failure of fusion of maxillary process with medial nasal process results into unilateral or bilateral isolated cleft lip (CL), respectively, and unilateral or bilateral failure of fusion of palatine process and primary palate leads to cleft palate (CP) with unilateral or bilateral CL, respectively. CP is caused because of nonjoining of two palatine processes. Oral clefts affect about 1–25/10,000 new-borns worldwide,<sup>[1]</sup> and the prevalence of isolated CP and CL with or without isolated CP is approximately 1/700 live births, with ethnic and geographic variation.<sup>[2]</sup> Depending on the location of the nonfusion, the extent of involvement of the lip and or palate varies giving birth to various classifications and severity scores.

Various factors such as smoking, alcohol, steroids, anticonvulsants, and less or no intake of folic acid and multivitamins in the first trimester of pregnancy are known to cause OFCs. Children with OFCs may be associated with

involvement of other systems. The majority of these OFCs are nonsyndromic. Syndromic and nonsyndromic OFC may have shown connection with involvement of other systems in the remarkable number of cases.<sup>[3]</sup> Advances in syndrome delineation and medical genetics have demonstrated that most of the clinical entities are an expression of genetic variability. In single gene disorders, abnormalities are seen and group of abnormalities are associated with monogenic syndrome.<sup>[3]</sup> Four hundred and eighty-seven monogenic syndromes were diagnosed in the 2001 version of the London Dysmorphology database.<sup>[4]</sup> When the syndromes involve a clinically important change in structure and/or number of chromosomal, they are termed as chromosomal syndrome. Trisomy 13 and 18 and the 4p are chromosomal aberrations (CAs) which result into


Address for correspondence: Dr. Anjali Satyen Sabnis, Department of Anatomy, MGM Medical College and Hospital, Kamothe, Navi Mumbai - 410 209, Maharashtra, India. E-mail: [anjalisabnis@gmail.com](mailto:anjalisabnis@gmail.com)

Submitted: 14-May-2021  
Accepted: 08-Oct-2021

Revised: 03-Oct-2021  
Published: 28-Oct-2021

This is an open access journal, and articles are distributed under the terms of the Creative Commons Attribution-NonCommercial-ShareAlike 4.0 License, which allows others to remix, tweak, and build upon the work non-commercially, as long as appropriate credit is given and the new creations are licensed under the identical terms.

For reprints contact: [WKHLRPMedknow\\_reprints@wolterskluwer.com](mailto:WKHLRPMedknow_reprints@wolterskluwer.com)

Access this article online	
Quick Response Code: 	Website: <a href="http://www.njca.info">www.njca.info</a>
DOI: 10.4103/NJCA.NJCA_60_21	


*[Handwritten signature]*  
MGM Dental College and Hospital,  
Navi Mumbai, Maharashtra

*[Handwritten signature]*  
MGM Dental College and Hospital,  
Navi Mumbai, Maharashtra



Available online at  
**ScienceDirect**  
 www.sciencedirect.com

Elsevier Masson France  
**EM|consulte**  
 www.em-consulte.com



Original Article

# Traumatic optic neuropathy in orbital wall fractures- diagnostic parameters and treatment outcomes: A prospective observational study

Srivalli Natarajan<sup>a,\*</sup>, Padmakar S. Baviskar<sup>a</sup>, Adil Gandevivala<sup>a</sup>, Himika Gupta<sup>b</sup>, Shruti N. Vichare<sup>a</sup>

<sup>a</sup> Department of Oral and Maxillofacial Surgery, Mahatma Gandhi Missions Dental College and Hospital, Sector 1, Kamothe, Navi Mumbai, Maharashtra 410209, India

<sup>b</sup> Honorary Ophthalmologist and Oculoplastic Surgeon, MCM New Bombay Hospital, Sector 3, Vashi, Navi Mumbai, Maharashtra 400703, India

**ARTICLE INFO**

**History:**  
 Received 2 March 2021  
 Accepted 21 June 2021  
 Available online xxx

**Keywords:**  
 Traumatic optic neuropathy  
 Visual acuity  
 Visual field orbital wall fractures  
 Mega dose steroid therapy  
 Visual evoked potential

**ABSTRACT**

**Introduction:** The aim of the study was to evaluate the associated patterns of orbital wall fractures, diagnostic parameters of Traumatic optic neuropathy and its progress with Mega dose steroid therapy.  
**Materials and Methods:** 25 patients with unilateral orbital wall fractures of traumatic aetiology were evaluated with ophthalmologic and radiographic parameters. All patients were prescribed Mega Dose Intravenous steroids irrespective of the timing of presentation. Ophthalmic assessment was repeated for same parameters every alternate day upto 2 weeks.  
**Results:** Lateral orbital wall was found to be most commonly involved. Visual acuity, Pupillary Reactivity, Visual Field and Visual Evoked Potential showed statistically significant improvement post steroid therapy in early as well as late presenters.  
**Discussion:** Highest incidence of Traumatic optic neuropathy was noted in multiple linear orbital wall fractures with highest incidence with lateral orbital wall involvement. Literature regarding Choice and timing of initiation of steroids based on timing of presentation is inadequate to justify skipping steroids to observe or undertake surgical intervention. In the present study marked improvement was noted post steroid therapy regardless of timing of presentation. The authors conclude that Visual evoked potential should be objectively tested and Mega dose steroid therapy should be initiated for all patients with Traumatic optic neuropathy for maximum benefit to the patient.

© 2021 Elsevier Masson SAS. All rights reserved.

**1. Introduction**

Orbital fractures are most commonly caused by motor vehicle accidents, followed by falls, assault and sport injuries. In India it has been estimated that over 50,000 people suffer from some form of facial trauma and craniofacial fractures every year [1]. Over 10,000 develop optic nerve injury with severe visual disturbances with a reported incidence of 2 to 5% [2].

Traumatic Optic Neuropathy (TRON) can be defined as an impact injury to the optic nerve that results in complete or partial loss of function. Trauma to axons may be direct or indirect [2]. Indirect optic nerve injury occurs by transmission of compression forces via orbital

bones to orbital apex and optic canal following blunt head trauma. Direct optic nerve injury occurs due to anatomical disruption of nerve fibres from penetrating orbital trauma, bone fragments within optic canal or nerve sheath hematomas [3]. TRON is a clinical diagnosis supported by a history of direct or indirect trauma to the head or face referring to any insult to the optic nerve secondary to trauma [4]. It can be classified depending on the site of injury (Optic nerve head, intraorbital, intracanalicular or intracranial) and according to the mode of injury with a reported incidence of 2–5% [5].

Management of TRON remains controversial as there is a general lack of understanding of pathophysiology involved, difficulty in timely diagnosis, infrequency of the injury and inability to obtain a reliable follow up. Failure to assess visual function as objectively possible in patients who have craniofacial fractures may lead to potentially treatable ophthalmic pathology not being identified early and have possible Medico-legal implications [6]. The importance of early recognition of TRON in Craniofacial fractures with Orbital Wall Fractures (OWFs) cannot be underestimated as management of ocular injury may take precedence over the surgical treatment of orbital fractures. Fracture repair in the setting of occult ocular injuries may

**Abbreviations:** CT, Computed Tomography; EOM, Extra-ocular motility; FxMxRXLX, F= Orbital Floor, M= Medial Wall, L= Lateral wall, R= Orbital Roof; IV, Intravenous; RTA, Road traffic accidents; OWFs, Orbital Wall Fractures; OV, Orbital Volume; ORIF, Open Reduction Internal Fixation; PR, Pupillary Reactivity; TRON, Traumatic Optic Neuropathy; VA, Visual acuity; VF, Visual Field; VEP, Visual Evoked Potential

\* Corresponding author.

E-mail address: srivalli.shrikant@gmail.com (S. Natarajan).

<https://doi.org/10.1016/j.jormas.2021.06.010>

2468-7855/© 2021 Elsevier Masson SAS. All rights reserved.

Please cite this article as: Natarajan, P.S., Baviskar, A., Gandevivala, A., Gupta, H., Vichare, S., Traumatic optic neuropathy in orbital wall fractures- diagnostic parameters and treatment outcomes: A prospective observational study, Journal of Stomatology oral and Maxillofacial Surgery (2021), <https://doi.org/10.1016/j.jormas.2021.06.010>

Dean  
 Mahatma Gandhi Missions Dental College and Hospital,  
 Kamothe, Navi Mumbai 410209

# Comparative Evaluation of Palatal Length, Speech Outcome, and Surgical Complications With Use of Von Langenbeck and Bardach 2 Flap Technique for the Repair of Cleft Palate: A Prospective Randomized Study

FACE  
1-11  
© The Author(s) 2021  
DOI: 10.1177/27325016211061804  
journals.sagepub.com/home/fac  
SAGE

Yash A. Oswal<sup>1</sup>, Srivalli Natarajan<sup>1</sup>, Gaurav S. Despande<sup>2,3</sup>, and Neha S. Patil<sup>4</sup>

## Abstract

**Purpose:** Successful closure of cleft palate is no more the sole criteria for determining the success of palatoplasty. Approximating soft palate musculature plays an equally important role. A continuous palate with muscular sling, speech and unhampered maxillary growth are 3 important goals of palatoplasty. The current study compared 2 popular palatoplasty techniques and also focused on other vital secondary parameters which would alter the final outcome of palatoplasty. **Methods:** Thirty-two primary cleft palate patients with repaired cleft lip ranging from 4 to 30 years were randomly and equally divided into 2 groups. Group A underwent Langenbeck and Group B underwent Bardach palatoplasty. Sommerlad's Intra-Velar Veloplasty was performed in all patients. The patients were evaluated for certain palatal and cleft measurements, speech, and surgical complications. The study also compared impact of cleft severity on speech and complications. **Results:** All the patients showed improvement in palatal length and speech. Significant palatal lengthening was achieved by Bardach as compared to Langenbeck palatoplasty ( $P = .002$ ). Amongst the various speech parameters so compared Bardach group showed better speech articulation post-operatively ( $P = .020$ ). No significant difference was found between the 2 groups in relation to other speech parameters. Total 4 complications were encountered 2 belonging to each group. **Conclusion:** Hard palate cleft repair technique plays little role as far as speech outcomes are concerned. It was Intravelar Veloplasty which reestablished the velopharyngeal sphincter and improved the quality of speech. Hence restoring the muscular sling of soft palate using radical dissection should be stressed upon by the surgeons besides the closure of cleft. The current study found few confounding factors such as age, cleft width, and Veau's class which altered the speech outcomes and/or complications of palatoplasty.

## Keywords

palatoplasty, cleft palate, Von Langenbeck, Bardach, Sommerlad's IVV, cleft speech

## Introduction

Numerous palatoplasties mentioned in literature for correction of cleft palate are the results of principles learned through years of practice. Von Langenbeck and Bardach palatoplasty are 2 of the popular palatal repair techniques used until today.<sup>1</sup> Besides the techniques of hard palate repair for achieving good palatal length, correcting abnormal palatal musculature is imperative in achieving optimum speech and deciding the long-term success of palatoplasty.<sup>2-7</sup> Evaluating the palatal length, speech, and surgical complications thus determines the success or failure of any palatoplasty. To our knowledge there is no available study which

has compared 2 palatoplasties in terms of all these vital functionally relevant parameters. Also, numerous other factors such as age, Veau's class, Randall's class, cleft width, and

<sup>1</sup>MGM Dental College and Hospital, Navi Mumbai, India

<sup>2</sup>MGM Institute of Health Science, Navi Mumbai, India

<sup>3</sup>Penn State Hershey School of Medicine, Hershey, PA

<sup>4</sup>MGM Medical College and Hospital, Navi Mumbai, India

### Corresponding Author:

Yash A. Oswal, Department of Oral and Maxillofacial Surgery, MGM Dental College and Hospital, Junction of NH4 and, Sion - Panvel Expressway, Sector 18, Navi Mumbai, Maharashtra 410209, India. Email: dryashoswal@gmail.com

M.G.M. Dental College and Hospital  
Kamothia, Navi Mumbai 410209

M.G.M. Dental College and Hospital  
Kamothia, Navi Mumbai 410209

## *International Journal of Scientific Research and Reviews*

### **Need of the Hour : Early and Rapid Diagnosis of Black Fungus (Mucormycosis) Maiming the Covid Patients in India!!!**

**Ujwala M.<sup>1</sup>, \*Shweta M.<sup>2</sup>, Navdeep K.<sup>2</sup>, Haripriya K.<sup>3</sup>, Dr.Srivalli S.<sup>4</sup>**

<sup>1</sup>Department of Pathology, MGM's Medical College and Hospital, Navi Mumbai. MH, India

<sup>2</sup>Department of Pathology, MGM's Medical College and Hospital, Navi Mumbai. MH, India

<sup>3</sup>Department of Microbiology, MGM's Medical College and Hospital, Navi Mumbai. MH, India

<sup>4</sup>Oral and maxillofacial surgery, MGM's Medical College and Hospital, Navi Mumbai. MH, India

#### **ABSTRACT:**

Mucormycosis is a very aggressive invasive fungal disease. It is a fungal emergency that affects a variety of patient groups. The disease, previously termed zygomycosis, is caused by mucoralean fungi, which have collectively also been called Mucormycetes.

Two cases a 55 year old male patient and 50 year old female patient who were previously treated for covid infection two months back came to MGM hospital with the complaints of headache, facial swelling, oral ulceration and difficulty in breathing which did not resolve on medication. Patients were further investigated for the same and a strong clinical suspicion of mucormycosis was made keeping in mind the post-covid status and use of steroid for treating the same. Now as mucormycosis is a clinical emergency, rapid diagnosis of the same was necessitated and scrapings of the ulcerated oral lesions and oral wash was taken and subjected to KOH mount and rapid cytological stains.

Oral cytology is often a good choice for identification of infective agents; being noninvasive therefore easily acceptable by patients, quick, inexpensive, simple, accurate and requiring minimum paraphernalia. Results are dependable; causative organisms of most of the lesions are frequently diagnosed—only in few cases, advanced ancillary techniques are required for final diagnosis.

**KEYWORDS:** Mucormycosis, Black fungus, Mucorales, Periodic acid Schiff (PAS), Gomori's Methanamine Silver (GMS), Oral Scrapings, Oral Wash.


#### **\*Corresponding author:**

**Dr. Shweta Munot**

Post-graduate student, Department of Pathology,

MGM's Medical College and Hospital, Navi Mumbai. MH, India

E-mail: [shwetamunot1994@gmail.com](mailto:shwetamunot1994@gmail.com)



Dean  
MGM's Dental College and Hospital,  
Navi Mumbai. MH, India

# Use of custom fabricated surgical jig to improve surgical outcomes in open reduction internal fixation of unilateral orbital fractures: A prospective clinical study

Padmakar S. Baviskar, Srivalli Natarajan

Access this article online

Quick Response Code:



Website:  
www.saudijophthalmol.org

DOI:  
10.4103/SJOPT.  
SJOPT\_49\_20

## Abstract:

**PURPOSE:** The aim of the study was to assess the efficacy of virtual planning and surgical guide jig to improve surgical outcomes of open reduction and internal fixation with restoration and correction of orbital volume (OV) in unilateral orbital wall fractures.

**METHODS:** Fifteen patients with unilateral orbital fractures were assessed with ophthalmologic and radiographic parameters. The orbit was divided into three zones on computed tomography to localize defects. Fractures were coded into Fx Mx Rx Lx (F = Orbital Floor, M = Medial Wall, L = Lateral wall, R = Orbital Roof) based on pattern and specific wall involved. 1-mm sections were used to make stereolithographic models, design the custom fabricated surgical jig for intraoperative use as a guide.

**RESULTS:** Pre- and postoperative ophthalmological parameters, OV, were compared with the contralateral normal orbit serving as the reference. Postoperative ophthalmological parameters showed significant improvement in terms of visual acuity, enophthalmos, dystopia, and traumatic optic neuropathy. OV changes were concentrated in Zones 2 and 3. OV showed adequate restoration postoperatively.

**CONCLUSION:** The surgical jig served as an efficient guide to improve surgical outcomes of open reduction internal fixation. Preplanned intraoperative positioning helped achieve adequate anatomical reduction and fixation with an adequate reconstruction of OV aiding the effective transfer of virtual surgical plan on the table with improved surgical outcomes in clinical performance and functional restitution.

**Clinical trial registration:** The Clinical Trials Registry of India (CTRI) Registration No.: CTRI/2019/11/021929.

### Keywords:

Orbital fractures, orbital reconstruction, orbital volume, orbital wall fractures, surgical jig, surgical outcome, traumatic optic neuropathy

## INTRODUCTION

The orbit is a unique anatomical structure that houses orbital contents like a glass jewel box. Poorly treated orbital wall fractures (OWF) culminate into long-term complications. The balance between the skeletal frame and the soft tissue appendages within is so subtle that even modest change leads to gross outcomes.

Computed tomography (CT) scans in different planes can calculate the discrepancy in the orbital volume (OV) and compare it with the

This is an open access journal, and articles are distributed under the terms of the Creative Commons Attribution-NonCommercial-ShareAlike 4.0 License, which allows others to remix, tweak, and build upon the work non-commercially, as long as appropriate credit is given and the new creations are licensed under the identical terms.

For reprints contact: WKHLRPMedknow\_reprints@wolterskluwer.com

normal contralateral orbit.<sup>[1]</sup> Computer-aided surgery and three-dimensional stereolithographic models (3D-SM) are noninvasive methods for precise surgical planning before surgery.

With emerging trends in imaging, utilization of 3D-SM and patient-specific implants (PSIs) OV measurements are becoming key parameters governing orbital reconstruction.<sup>[2]</sup> Even with the increasing use of PSI and virtual surgical planning (VSP), there is a paucity of evidence concerning intraoperative surgical guides. The use of an intraoperative guide in some form can improve the surgical outcomes, particularly in

**How to cite this article:** Baviskar PS, Natarajan S. Use of custom fabricated surgical jig to improve surgical outcomes in open reduction internal fixation of unilateral orbital fractures: A prospective clinical study. Saudi J Ophthalmol 0,0 0.

Department of Oral and Maxillofacial Surgery, MGM Dental College and Hospital, Kamothe, Sector 01, Navi Mumbai, Maharashtra, India

### Address for correspondence:

Dr. Padmakar Baviskar, Department of Oral and Maxillofacial Surgery, MGM Dental College and Hospital, Sector 1, Kamothe, Navi Mumbai - 410 209, Maharashtra, India. E-mail: drpadmakar22@gmail.com

Submitted: 30-Nov-2020

Revised: 28-Jun-2021

Accepted: 04-Aug-2021

Published: 17-Nov-2021

*CS*

M.G.M. Dental College and Hospital,  
Kamothe, Navi Mumbai

Down  
M.G.M. Dental College and Hospital,  
Kamothe, Navi Mumbai